

ESGO/ESTRO/ESP guidelines for the management of patients with endometrial carcinoma

Nicole Concin ^{1,2}, Xavier Matias-Guiu,^{3,4} Ignace Vergote,⁵ David Cibula,⁶ Mansoor Raza Mirza,⁷ Simone Marnitz,⁸ Jonathan Ledermann ⁹, Tjalling Bosse,¹⁰ Cyrus Chargari,¹¹ Anna Fagotti,¹² Christina Fotopoulou ¹³, Antonio Gonzalez Martin,¹⁴ Sigurd Lax,^{15,16} Domenica Lorusso,¹² Christian Marth,¹⁷ Philippe Morice,¹⁸ Remi A Nout,¹⁹ Dearbhaile O'Donnell,²⁰ Denis Querleu ^{12,21}, Maria Rosaria Raspollini,²² Jalid Sehoul,²³ Alina Sturdza,²⁴ Alexandra Taylor,²⁵ Anneke Westermann,²⁶ Pauline Wimberger,²⁷ Nicoletta Colombo,²⁸ François Planchamp,²⁹ Carien L Creutzberg³⁰

For numbered affiliations see end of article.

Correspondence to

Nicole Concin, Department of Gynecology and Obstetrics, Innsbruck Medical University, Innsbruck 6020, Austria; nicole.concin@i-med.ac.at

For 'Presented at statement' see end of article.

Received 7 November 2020
Accepted 16 November 2020
Published Online First
18 December 2020

ABSTRACT

A European consensus conference on endometrial carcinoma was held in 2014 to produce multi-disciplinary evidence-based guidelines on selected questions. Given the large body of literature on the management of endometrial carcinoma published since 2014, the European Society of Gynaecological Oncology (ESGO), the European Society for Radiotherapy and Oncology (ESTRO), and the European Society of Pathology (ESP) jointly decided to update these evidence-based guidelines and to cover new topics in order to improve the quality of care for women with endometrial carcinoma across Europe and worldwide.

INTRODUCTION

Endometrial carcinoma is the most common gynecological cancer in Europe, with a 5-year prevalence of 34.7% (445 805 cases).¹ The estimated number of new endometrial carcinoma cases in Europe in 2018 was 121 578 with 29 638 deaths, and the incidence has been rising with aging and increased obesity of the population. The EUROcare-5 study, published in 2015, reported a 5-year relative survival of 76% for European women diagnosed with endometrial carcinoma in 2000–2007, ranging from 72.9% in Eastern Europe to 83.2% in Northern Europe.² The observed geographic difference might be partially attributable to tangible differences in the prevalence of endometrioid sub-types among regions. Furthermore, differences in patient characteristics and histopathologic features of the disease impact both on patient prognosis and the recommended treatment approach.

A consensus conference including representation from the European Society of Medical Oncology (ESMO), the European Society of Gynaecological Oncology (ESGO), and the European Society for Radiotherapy and Oncology (ESTRO) was held in 2014 with the aim to produce multi-disciplinary evidence-based guidelines on 12 selected questions in order to complement the ESMO clinical practice guidelines previously published.^{3–6} ESGO, ESTRO, and the European Society of Pathology (ESP) jointly decided to update these evidence-based guidelines

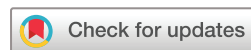and, moreover, to cover new topics in order to provide comprehensive guidelines on all relevant issues of diagnosis and treatment in endometrial carcinoma in a multi-disciplinary setting. These guidelines are intended for use by gynecological oncologists, general gynecologists, surgeons, radiation oncologists, pathologists, medical and clinical oncologists, radiologists, general practitioners, palliative care teams, and allied health professionals.

RESPONSIBILITIES

These guidelines are a statement of evidence and consensus of the authors regarding their views of currently accepted approaches for the management of patients with endometrial carcinoma. Any clinician applying or consulting these guidelines is expected to use independent medical judgment in the context of individual clinical circumstances to determine any patient's care or treatment. These guidelines make no warranties of any kind regarding their content, use, or application, and the authors disclaim any responsibility for their application or use in any way.

METHODS

The guidelines were developed using a five-step process as defined by the ESGO Guideline Committee (see [Figure 1](#)). The strengths of the process include creation of a multi-disciplinary international development group, use of scientific evidence and international expert consensus to support the guidelines, and use of an international external review process (physicians and patients). This development process involved three meetings of the international development group chaired by Professor Nicole Concin (Medical University of Innsbruck, Innsbruck, Austria/ Evangelische Kliniken Essen-Mitte, Essen, Germany, for ESGO), Professor Carien L Creutzberg (Leiden University Medical Center, Leiden, the Netherlands, for ESTRO), and Professor Xavier Matias-Guiu (Department of Pathology, Hospital Universitari Arnau de Vilanova and Hospital Universitari de Bellvitge,



© IGCS and ESGO 2021. No commercial re-use. See rights and permissions. Published by BMJ.

To cite: Concin N, Matias-Guiu X, Vergote I, et al. *Int J Gynecol Cancer* 2021;**31**:12–39.

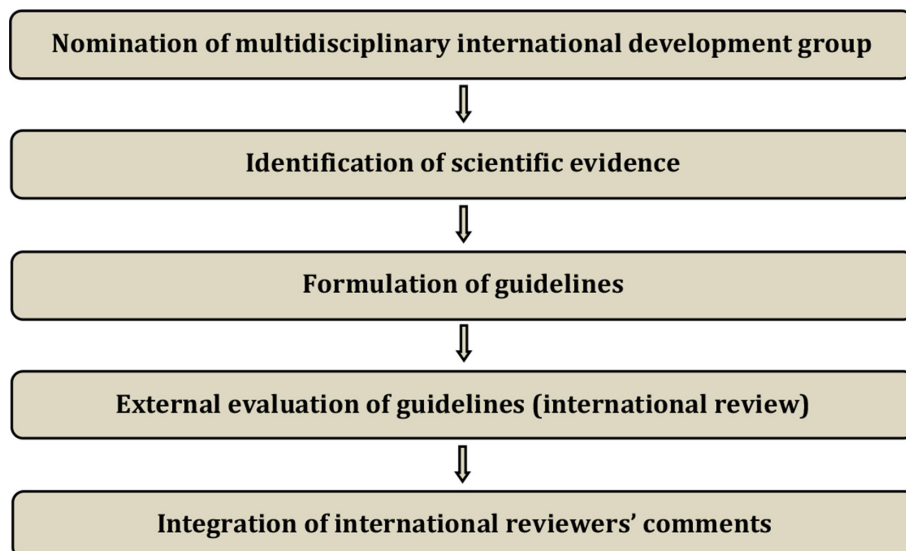


Figure 1 Development process.

Irballeida, Idibell, Universities of Lleida and Barcelona, CIBERONC, Spain, for ESP).

ESGO/ESTRO/ESP nominated practising clinicians who are involved in the management of patients with endometrial carcinoma and have demonstrated leadership in the clinical management of patients through research, administrative responsibilities, and/or committee membership to serve on the expert panel. The objective was to assemble a multi-disciplinary panel and it was therefore essential to include professionals from relevant disciplines (gynecological oncology and gynecology, medical, clinical and radiation oncology, pathology) to contribute to the validity and acceptability of the guidelines. To ensure that the statements were evidence based, the current literature was reviewed and critically appraised. A systematic literature review of relevant studies published between January 2014 and June 2019 was carried out using the MEDLINE database (see online supplemental appendix 1). The literature search was limited to publications in English. Priority was given to high-quality systematic reviews, meta-analyses, and randomized controlled trials, but studies of lower levels of evidence were also evaluated. The search strategy excluded editorials, letters, and *in vitro* studies. The reference list of each identified article was also reviewed for other potentially relevant articles.

The development group developed guidelines for all the topics. The guidelines were retained if they were supported by a sufficiently high level of scientific evidence and/or when a large consensus among experts was obtained. An adapted version of the 'Infectious Diseases Society of America-United States Public Health Service Grading System' was used to define the level of evidence and grade of recommendation for each of the recommendations⁷ (see Table 1). In the absence of any clear scientific evidence, judgment was based on the professional experience and consensus of the development group.

ESGO/ESTRO/ESP established a large multi-disciplinary panel of practicing clinicians who provide care to patients with endometrial carcinoma to act as independent expert reviewers for the guidelines developed. These reviewers were selected according to their expertise, had to be still involved in clinical practice, and were from different European and non-European countries to ensure

global perspective. Patients with endometrial carcinoma were also included. These independent reviewers were asked to evaluate each recommendation according to its relevance and feasibility in clinical practice (only physicians), so that comprehensive quantitative and qualitative evaluations of the guidelines were completed. Patients were asked to evaluate qualitatively each recommendation (according to their experience, personal perceptions, etc).

Table 1 Levels of evidence and grades of recommendations

Levels of evidence	
I	Evidence from at least one large randomized controlled trial of good methodological quality (low potential for bias) or meta-analyses of well-conducted randomized trials without heterogeneity
II	Small randomized trials or large randomized trials with a suspicion of bias (lower methodological quality) or meta-analyses of such trials or of trials with demonstrated heterogeneity
III	Prospective cohort studies
IV	Retrospective cohort studies or case-control studies
V	Studies without control group, case reports, expert opinions
Grades of recommendations	
A	Strong evidence for efficacy with a substantial clinical benefit, strongly recommended
B	Strong or moderate evidence for efficacy but with a limited clinical benefit, generally recommended
C	Insufficient evidence for efficacy or benefit does not outweigh the risk or the disadvantages (adverse events, costs, etc), optional
D	Moderate evidence against efficacy or for adverse outcome, generally not recommended
E	Strong evidence against efficacy or for adverse outcome, never recommended

Joint statement

Evaluations of the external reviewers (n=191) were pooled and discussed by the international development group before finalising the guidelines. The list of the 191 external reviewers is available in online supplemental appendix 2.

GENERAL RECOMMENDATIONS

- ▶ Planning of staging and treatment should be made on a multi-disciplinary basis (generally at a tumor board meeting, composed according to local guidelines) and based on the comprehensive and precise knowledge of prognostic and predictive factors for outcome, morbidity, and quality of life (V, A).
- ▶ Patients should be carefully counseled about the suggested diagnostic and treatment plan and potential alternatives, including risks and benefits of all options (V, A).
- ▶ Treatment should be undertaken in a specialized center by a dedicated team of specialists in the diagnosis and management of gynecological cancers, especially in high-risk and/or advanced stage disease (V, A).

IDENTIFICATION AND SURVEILLANCE OF WOMEN WITH A PATHOGENIC GERMLINE VARIANT IN A LYNCH SYNDROME-ASSOCIATED GENE

Approximately 3% of all endometrial carcinomas and about 10% of mismatch repair deficient (MMRd)/microsatellite unstable endometrial carcinomas are causally related to germline mutations of one of the MMR genes *MLH1*, *PMS2*, *MSH2* and *MSH6*.⁸ Testing for MMR status/microsatellite instability (MSI) in endometrial carcinoma patients has been shown to be relevant for four reasons: (1) diagnostic, as MMRd/MSI is considered a marker for endometrioid-type endometrial carcinoma; (2) pre-screening to identify patients at higher risk for having Lynch syndrome; (3) prognostic, as identified by The Cancer Genome Atlas (TCGA, see below for molecular classification); and (4) predictive for potential utility of immune checkpoint inhibitor therapy. The International Society of Gynecological Pathology (ISGyP) has recommended testing for MMR status/MSI in all endometrial carcinoma samples, irrespective of age.⁹ This has also been recommended in other society statements and recommendations, such as the Manchester International Consensus Group recommendations, whenever resources are available.¹⁰

The preferred approach (widely available and cost-effective) to identifying patients with a higher chance of having Lynch syndrome is by MMR-immunohistochemistry (IHC) on well preserved tumor tissue. MMR-IHC is a reliable method to assess MMR status, and in addition provides information on the altered gene/protein. ISGyP guidelines therefore recommend MMR-IHC as the preferred test.⁹ MMR-IHC consists of the assessment of the expression of four MMR proteins (*MLH1*, *PMS2*, *MSH6*, and *MSH2*). A simplified two-antibody (*PMS2* and *MSH6*) approach has been proposed as a cost-effective alternative.^{11–13} This procedure still requires performing *MLH1* and *MSH2* IHC in cases with any abnormal staining of *PMS2* and/or *MSH6*. Molecular analyses for the microsatellite status (MSI-test) are an alternative, but are more laborious, require non-neoplastic tissue, are more expensive, and do not provide information on the gene affected. For optimal pre-selection of patients at risk for having Lynch syndrome, both approaches require the analysis of *MLH1* promoter methylation status in cases with loss of

MLH1/PMS2 expression. Testing for MMRd by IHC or MSI by PCR-based methods does not allow direct identification of patients with Lynch syndrome since MMRd/MSI is frequently due to sporadic events such as bi-allelic somatic mutations or hypermethylation. In the absence of hypermethylation, referral to genetic counseling is recommended to evaluate the presence of a germline mutation. When familial history is highly suspicious of Lynch syndrome, genetic counseling is recommended independent of the MMR status.

The cumulative incidences for cancer depend on the specific mutation in women with Lynch syndrome. For endometrial carcinoma, the cumulative incidences at 70 years are 34%, 51%, 49%, and 24% for *MLH1*, *MSH2*, *MSH6*, and *PMS2* mutation carriers, respectively, and for ovarian cancer 11%, 15%, 0%, and 0%, respectively.¹⁴ Furthermore, the age of cancer onset in Lynch syndrome varies among specific mutated genes and types of mutations.¹⁵ Ryan *et al* suggest gynecological surveillance to be appropriate from age 30 years for those with *MSH2* mutations, from age 35 years for those with nontruncating *MLH1* mutations, and from age 40 years for those with *MSH6* and truncating *MLH1* mutations. Women with heterozygous *PMS2* mutations do not warrant gynecological surveillance because their absolute risk of gynecological cancer is very low. As part of a retrospective study, Lachiewicz *et al* reported a risk of any occult malignancy during prophylactic surgery for women with Lynch syndrome or hereditary non-polyposis colorectal cancer to be up to 17%.¹⁶ Thus, these patients should be counseled about the risk of detection of gynecological cancer at prophylactic surgery.

Recommendations

- ▶ To identify patients with Lynch syndrome and triage for germline mutational analysis, MMR IHC (plus analysis of *MLH1* promoter methylation status in case of immunohistochemical loss of *MLH1/PMS2* expression) or MSI tests should be performed in all endometrial carcinomas, irrespective of histologic subtype of the tumor (III, B).
- ▶ Endometrial carcinoma patients identified as having an increased risk of Lynch syndrome should be offered genetic counseling (III, B).
- ▶ Surveillance for endometrial carcinoma in Lynch syndrome mutation carriers should in general start at the age of 35 years; however, individual factors need to be taken into consideration (tailored surveillance programs). The decision on the starting age of surveillance should integrate knowledge on the specific mutation and history of onset of events in the family (IV, B).
- ▶ Surveillance of the endometrium by annual transvaginal ultrasound (TVUS) and annual or biennial biopsy until hysterectomy should be considered in all Lynch syndrome mutation carriers (IV, B).
- ▶ Hysterectomy and bilateral salpingo-oophorectomy to prevent endometrial and ovarian cancer should be performed at the completion of childbearing and preferably before the age of 40 years. All the pros and cons of prophylactic surgery must be discussed including the risk of occult gynecological cancer detection at prophylactic surgery. Estrogen replacement therapy should be suggested if bilateral salpingo-oophorectomy is performed in pre-menopausal women (IV, B).

MOLECULAR MARKERS FOR ENDOMETRIAL CARCINOMA DIAGNOSIS AND AS DETERMINANTS FOR TREATMENT DECISIONS

Different types of endometrial carcinoma have specific histological and molecular features, precursor lesions and natural histories. Conventional pathologic analysis remains an important tool for tumor stratification, but suffers from inter-observer variation. Different groups have applied a diagnostic algorithm using three immunohistochemical markers (p53, MSH6 and PMS2) and one molecular test (mutation analysis of the exonuclease domain of POLE) to identify prognostic groups analogous to the TCGA molecular-based classification.^{17–21} The feasibility of this approach was confirmed by a large number of publications that have all consistently reported prognostic relevance particularly in high-grade and high-risk tumors in several independent cohorts and prospective clinical trials.²² To apply this molecular classification, all these diagnostic tests need to be performed. Performing one of the surrogate marker tests in isolation is insufficient, as a combination of positive tests can occur in approximately 5% of all carcinomas. The diagnostic algorithm to classify these so-called 'multiple classifiers' has been described recently.^{23 24} In addition, endometrial carcinoma should only be classified as *POLE*-mutated (*POLE*mut) when pathogenic variants of *POLE* are identified in the gene's exonuclease domain.^{25 26}

This surrogate marker approach to the molecular-based classification has been demonstrated to be prognostically informative in low-, intermediate-, and high-risk endometrial carcinoma. Smaller studies showed that the molecular classification is also applicable to non-endometrioid tumors including serous, clear cell, undifferentiated carcinomas, and uterine carcinosarcomas. For adjuvant treatment recommendations, the molecular classification seems to be particularly relevant in the context of high-grade and/or high-risk endometrial carcinomas. Application of the molecular classification in high-grade and/or high-risk endometrial carcinomas shows that there is a group of patients with an excellent prognosis—that is, the *POLE*mut tumors—and a group with a poor prognosis—that is, the p53-abnormal (p53abn) tumors. Endometrial carcinomas with MMRd or non-specific molecular profile (NSMP) have an intermediate prognosis. However, the molecular surrogate is not perfect. Immunohistochemical demonstration of p53abn is a good but not perfect surrogate of *TP53* mutation. Furthermore, a small proportion of high copy number tumors do not show *TP53* mutations. To minimize these limitations, an integrated analysis combining traditional pathologic and molecular results seems ideal. In low-risk endometrioid carcinomas, the molecular classification may not be required.^{27 28}

The proposed molecular classification of endometrial carcinoma is clinically feasible using a limited set of diagnostic tests. Using this novel classification is encouraged. All diagnostic tests should be performed in conjunction due to the occurrence of 'double classifiers'.²³ Clinical management may be particularly impacted by the molecular classification in scenarios where adjuvant chemotherapy is considered (high-grade/high-risk disease). Thus, these cases should be prioritized when there is a lack of sufficient resources to perform this classification on all endometrial carcinomas. If molecular classification tools are not available, endometrial carcinoma classification should be based on traditional pathologic features.

There is still room for other biomarkers that may be potentially useful in the big group of low-grade endometrioid carcinoma with NSMP, such as L1CAM expression or mutations in *CTNNB1*.^{29–32}

Recommendations

- ▶ Molecular classification is encouraged in all endometrial carcinomas, especially high-grade tumors (IV, B).
- ▶ *POLE* mutation analysis may be omitted in low-risk and intermediate-risk endometrial carcinoma with low-grade histology (IV, C).

DEFINITION OF PROGNOSTIC RISK GROUPS INTEGRATING MOLECULAR MARKERS

There is overwhelming evidence that traditional pathologic features, such as histopathologic type, grade, myometrial invasion, and lymphovascular space invasion (LVSI), are important in assessing prognosis, as recommended in the ISGyP guidelines.⁹ Histopathologic typing should be performed according to the WHO Classification of Tumors (5th edition).³³ A binary International Federation of Gynecology and Obstetrics (FIGO) grading is recommended, which considers grade 1 and grade 2 carcinomas as low-grade and grade 3 carcinomas as high-grade. For the assessment of myometrial invasion, account needs to be taken of the endo-myometrial junction which is undulating.³⁴ Focal LVSI is defined by the presence of a single focus around the tumor, substantial LVSI as multifocal or diffuse arrangement of LVSI or the presence of tumor cells in five or more lymphovascular spaces. The molecular classification adds another layer of information to the conventional morphologic features and therefore should be integrated in the pathologic report.

Recommendations

- ▶ Histopathologic type, grade, myometrial invasion, and LVSI (no/focal/substantial) should be recorded in all patients with endometrial carcinoma (V, A).
- ▶ The definition of prognostic risk groups is presented in [Table 2](#) for both situations when molecular classification is known or unknown.

PRE- AND INTRA-OPERATIVE WORK-UP

Risk group allocation on biopsy according to the WHO Classification of Tumors (5th edition) and FIGO grading of endometrial carcinoma is required for adequate planning of therapy.³³ Histopathologic grade has prognostic relevance. A modified binary FIGO grading is recommended lumping together grade 1 and grade 2 endometrioid carcinomas as low-grade and grade 3 as high-grade.

Magnetic resonance imaging (MRI) techniques are highly specific in the assessment of deep myometrial invasion, cervical stromal involvement, and lymph node metastasis.^{35–82} The diagnostic performance of TVUS and MRI for detecting myometrial invasion in endometrial carcinoma are quite similar.^{39 44 56 83–88} Of note, pre-operative ultrasound assessment of deep myometrial and cervical stromal invasion in endometrial carcinoma is best performed by an expert sonographer as, compared with gynecologists, they show a greater degree of agreement with histopathology and greater inter-observer reproducibility.⁸⁴ Positron emission tomography (PET) scanning has an excellent specificity for the pre-operative assessment of lymph node metastases in patients with endometrial carcinoma. Its moderate sensitivity for detecting lymph node metastases during pre-operative staging probably reflects the need

Joint statement

Table 2 Definition of prognostic risk groups

Risk group	Molecular classification unknown	Molecular classification known*†
Low	<ul style="list-style-type: none"> ▶ Stage IA endometrioid + low-grade‡ + LVSI negative or focal 	<ul style="list-style-type: none"> ▶ Stage I-II POLEmut endometrial carcinoma, no residual disease ▶ Stage IA MMRd/NSMP endometrioid carcinoma + low-grade‡ + LVSI negative or focal
Intermediate	<ul style="list-style-type: none"> ▶ Stage IB endometrioid + low-grade‡ + LVSI negative or focal ▶ Stage IA endometrioid + high-grade‡ + LVSI negative or focal ▶ Stage IA non-endometrioid (serous, clear cell, undifferentiated carcinoma, carcinosarcoma, mixed) without myometrial invasion 	<ul style="list-style-type: none"> ▶ Stage IB MMRd/NSMP endometrioid carcinoma + low-grade‡ + LVSI negative or focal ▶ Stage IA MMRd/NSMP endometrioid carcinoma + high-grade‡ + LVSI negative or focal ▶ Stage IA p53abn and/or non-endometrioid (serous, clear cell, undifferentiated carcinoma, carcinosarcoma, mixed) without myometrial invasion
High-intermediate	<ul style="list-style-type: none"> ▶ Stage I endometrioid + substantial LVSI regardless of grade and depth of invasion ▶ Stage IB endometrioid high-grade‡ regardless of LVSI status ▶ Stage II 	<ul style="list-style-type: none"> ▶ Stage I MMRd/NSMP endometrioid carcinoma + substantial LVSI regardless of grade and depth of invasion ▶ Stage IB MMRd/NSMP endometrioid carcinoma high-grade‡ regardless of LVSI status ▶ Stage II MMRd/NSMP endometrioid carcinoma
High	<ul style="list-style-type: none"> ▶ Stage III–IVA with no residual disease ▶ Stage I–IVA non-endometrioid (serous, clear cell, undifferentiated carcinoma, carcinosarcoma, mixed) with myometrial invasion, and with no residual disease 	<ul style="list-style-type: none"> ▶ Stage III–IVA MMRd/NSMP endometrioid carcinoma with no residual disease ▶ Stage I–IVA p53abn endometrial carcinoma with myometrial invasion, with no residual disease ▶ Stage I–IVA NSMP/MMRd serous, undifferentiated carcinoma, carcinosarcoma with myometrial invasion, with no residual disease
Advanced metastatic	<ul style="list-style-type: none"> ▶ Stage III–IVA with residual disease ▶ Stage IVB 	<ul style="list-style-type: none"> ▶ Stage III–IVA with residual disease of any molecular type ▶ Stage IVB of any molecular type

*For stage III–IVA *POLEmut* endometrial carcinoma and stage I–IVA *MMRd* or *NSMP* clear cell carcinoma with myometrial invasion, insufficient data are available to allocate these patients to a prognostic risk group in the molecular classification. Prospective registries are recommended.

†See text on how to assign double classifiers (eg, patients with both *POLEmut* and *p53abn* should be managed as *POLEmut*).

‡According to the binary FIGO grading, grade 1 and grade 2 carcinomas are considered as low-grade and grade 3 carcinomas are considered as high-grade.

LVSI, lymphovascular space invasion; *MMRd*, mismatch repair deficient; *NSMP*, non-specific molecular profile; *p53abn*, *p53* abnormal; *POLEmut*, polymerase-mutated.

for a sufficient number of neoplastic cells to induce ¹⁸F-fluoro-2-deoxy-D-glucose hypermetabolism.^{89–100} The usefulness of maximal standardized uptake value in classifying patients into pre-defined risk groups is limited.¹⁰¹ A pre-operative CT scan has a clinical utility in patients with endometrial carcinoma in detecting metastatic disease.^{102 103}

Frozen section of endometrial biopsy material is obsolete. Myometrial invasion should not be assessed by frozen section because of poor reproducibility and agreement with definitive paraffin sections. Since sentinel node biopsy is increasingly used, the need for intra-operative assessment of myometrial invasion has become less important. Moreover, some of the biomarkers that have been proposed require optimal management of the surgical specimen with high quality pre-analytical issues such as appropriate fixation conditions. Performing frozen sections can lead to incorrect control of pre-analytical conditions, sometimes even leading to incorrect assessment of LVSI due to artifactual displacement of

tumor cells into vascular spaces during processing. In addition, the freezing of tissue before fixation and further processing interferes with an optimal pre-analytical procedure required for standardized histopathologic diagnosis.

Recommendations

- ▶ Histopathologic tumor type and grade in endometrial biopsy is required (IV, A).
- ▶ Pre-operative mandatory work-up includes: family history; general assessment and inventory of co-morbidities; geriatric assessment, if appropriate; clinical examination, including pelvic examination; expert transvaginal or transrectal ultrasound or pelvic MRI (IV, C).
- ▶ Depending on clinical and pathologic risk, additional imaging modalities (thoracic, abdominal and pelvic CT scan, MRI, PET scan, or ultrasound) should be considered to assess ovarian, nodal, peritoneal, and other sites of metastatic disease (IV, C).

- ▶ Intra-operative frozen section is not encouraged for myometrial invasion assessment because of poor reproducibility and interference with adequate pathologic processing (IV, A).

EARLY STAGE DISEASE

Surgical management of apparent stage I/II endometrial carcinomas

Minimally invasive approach

Two randomized prospective studies comparing minimally invasive with open surgeries showed similar survival with quicker recovery with the minimally invasive approach.^{104 105} More recently, pooled analyses of randomized prospective studies including, notably, these two studies and multiple retrospective and prospective studies also support the use of minimally invasive surgery for patients including those with high-risk endometrial carcinoma.^{106–171}

Recommendations

- ▶ Minimally invasive surgery is the preferred surgical approach, including patients with high-risk endometrial carcinoma (I, A).
- ▶ Any intra-peritoneal tumor spillage, including tumor rupture or morcellation (including in a bag), should be avoided (III, B).
- ▶ If vaginal extraction risks uterine rupture, other measures should be taken (eg, mini-laparotomy, use of endobag) (III, B).
- ▶ Tumors with metastases outside the uterus and cervix (excluding lymph node metastases) are relative contraindications for minimally invasive surgery (III, B).

Standard surgical procedures

In a randomized controlled trial comparing modified radical (Piver–Rutledge class II) hysterectomy to the standard extrafascial (Piver–Rutledge class I) or simple total hysterectomy in stage I endometrial carcinoma, Signorelli *et al* showed no differences in locoregional control and survival.¹⁷² The high risk of microscopic omental metastases in stage I serous and undifferentiated endometrial carcinoma and in carcinosarcoma suggests that omentectomy should be part of staging surgery in these patients.¹⁷³ The low rate of omental metastases in apparent clinical stage I endometrioid and clear cell carcinoma does not justify the procedure.¹⁷⁴ Although the risk of having occult (microscopic) omental metastases in carcinosarcoma is around 6%, staging omentectomy in these women is suggested. Identification of these cases will allow inclusion of patients with advanced stage disease into clinical trials.¹⁷⁵ Positive peritoneal cytology correlates with poor prognostic factors and poor survival; however, it is not part of FIGO staging and unclear if this should influence treatment decisions.^{176–178}

Recommendations

- ▶ Standard surgery is total hysterectomy with bilateral salpingo-oophorectomy without vaginal cuff resection (II, A).
- ▶ Staging infracolic omentectomy should be performed in clinical stage I serous endometrial carcinoma, carcinosarcoma, and undifferentiated carcinoma. It can be omitted in clear cell and endometrioid carcinoma in stage I disease (IV, B).
- ▶ Surgical re-staging can be considered in previously incompletely staged patients with high–intermediate-risk/high-risk disease if the outcome might have an implication for adjuvant treatment strategy (IV, B).

Lymph node staging

Sentinel node biopsy has been introduced as an alternative to lymph node dissection for lymph node staging and, if done according to state-of-art principles, a negative sentinel node is accepted to confirm pNO. Multiple studies, including prospective cohort ones, confirmed high sensitivity of sentinel lymph node status for lymph node staging in patients with early-stage endometrial carcinoma and support the impact of sentinel lymph node biopsy on surgical management and indications for adjuvant therapies.^{179–241} More intensive pathologic assessment of sentinel lymph node (sentinel lymph node ultrastaging) supports the detection of small metastases which could be missed by standard evaluation.^{214 232} Sentinel lymph node biopsy without dissection of other pelvic lymph nodes is associated with substantially lower risk of post-operative morbidity, especially lower leg lymphedema.²⁴² In a large group of patients with low-risk (myometrial invasion <50%, low-grade) endometrial carcinoma with sentinel lymph node biopsy, lymph node involvement was found in 6% of patients, half of them identified by pathologic ultrastaging.²⁴³ Patients with tumors without myometrial invasion did not have any positive sentinel lymph nodes. Four prospective cohort trials have shown high sensitivity to detect pelvic lymph node metastases and a high negative predictive value by applying a sentinel lymph node algorithm in high-risk/high-grade endometrial carcinomas in the hands of experienced surgeons.^{181 182 237 244}

Recently, a randomized controlled trial highlighted that the use of indocyanine green instead of methylene blue dye resulted in a significant increase in sentinel lymph node detection rates per hemipelvis in women with endometrial carcinoma undergoing minimally invasive surgery.²⁴⁵ Retrospective studies showed a similar prognosis for patients after full lymphadenectomy and sentinel lymph node biopsy only.^{179 201 220} High bilateral pelvic sentinel lymph node detection can be achieved when the tracer is injected into the cervix.^{180 246} A higher sentinel lymph node detection rate has been reported using near-infrared fluorescence in comparison to other techniques.²⁴⁷ A worse prognosis is associated with the presence of nodal micrometastases, especially in patients who do not receive adjuvant treatment.²⁴⁸ There is no evidence that the presence of isolated tumor cells (ITCs) has an impact on prognosis, and similar to other tumor sites, the stage would be pNO(i+). If pelvic lymph node involvement is reported either by sentinel lymph node frozen section or by the final pathology, para-aortic staging can be considered, either by imaging (with all limitations of the imaging modalities) or by surgery. It should be noted that, based on data from two large randomized trials, lymph node staging does not have a therapeutic value but is done to assess the extent of disease and to provide information for adjuvant treatment decisions.^{249 250} Frozen section on specimens regarded as sentinel lymph nodes can confirm the presence of lymph nodes and macrometastases but should not replace adequate pathologic processing and ultrastaging.

Recommendations

- ▶ Sentinel lymph node biopsy can be considered for staging purposes in patients with low-risk/intermediate-risk disease. It can be omitted in cases without myometrial invasion. Systematic lymphadenectomy is not recommended in this group (II, A).
- ▶ Surgical lymph node staging should be performed in patients with high–intermediate-risk/high-risk disease. Sentinel

Joint statement

lymph node biopsy is an acceptable alternative to systematic lymphadenectomy for lymph node staging in stage I/II (III, B).

- ▶ If sentinel lymph node biopsy is performed (II, A):
 - Indocyanine green with cervical injection is the preferred detection technique.
 - Tracer re-injection is an option if sentinel lymph node is not visualized upfront.
 - Side-specific systematic lymphadenectomy should be performed in high–intermediate-risk/high-risk patients if sentinel lymph node is not detected on either pelvic side.
 - Pathologic ultrastaging of sentinel lymph nodes is recommended.
- ▶ When a systematic lymphadenectomy is performed, pelvic and para-aortic infrarenal lymph node dissection is suggested (III, B).
- ▶ Presence of both macrometastases and micrometastases (<2 mm, pN1(mi)) is regarded as a metastatic involvement (IV, C).
- ▶ The prognostic significance of ITCs, pNO(i+), is still uncertain (IV, C).
- ▶ If pelvic lymph node involvement is found intra-operatively, further systematic pelvic lymph node dissection should be omitted. However, debulking of enlarged lymph nodes and para-aortic staging can be considered (IV, B).

Option for ovarian preservation and salpingectomy in stage I/II

A meta-analysis showed that there was no significant difference in overall survival between patients treated with ovarian preservation and bilateral salpingo-oophorectomy.²⁵¹ A similar result was achieved in young and pre-menopausal women. Disease-free survival of patients whose ovaries were preserved was slightly compromised, but this was not statistically significant. Ovarian preservation can be cautiously considered in specific clinical situations when treating young and pre-menopausal women with early stage endometrial carcinoma because it is not associated with a significant adverse impact on survival.^{252–254} Salpingectomy during hysterectomy is recommended to decrease the risk of high-grade serous ovarian carcinoma.²⁵⁵ Ovarian preservation is not recommended in patients with cancer family history involving ovarian cancer risk (eg, *BRCA* mutation, Lynch syndrome, etc), but oocyte cryopreservation might be considered.²⁵⁶

Recommendations

- ▶ Ovarian preservation can be considered in pre-menopausal patients aged <45 years with low-grade endometrioid endometrial carcinoma with myometrial invasion <50% and no obvious ovarian or other extra-uterine disease (IV, A).
- ▶ In cases of ovarian preservation, salpingectomy is recommended (IV, B).
- ▶ Ovarian preservation is not recommended for patients with cancer family history involving ovarian cancer risk (eg, *BRCA* mutation, Lynch syndrome, etc) (IV, B).

Radicality of surgery for clinical stage II

Radicality of hysterectomy (simple vs modified radical hysterectomy (type II)) in stage I–III endometrial carcinoma has no impact on local recurrence rate, disease-free survival, and overall survival. In a meta-analysis enrolling 2866 patients with stage II endometrial

carcinoma, radical hysterectomy did not show a significant survival benefit for either overall survival or progression-free survival compared with simple hysterectomy.²⁵⁷ The result remained consistent after it was adjusted for the possible impact of adjuvant radiotherapy.

Recommendations

- ▶ Total hysterectomy with bilateral salpingo-oophorectomy and lymph node staging is the surgical standard of care in patients with stage II endometrial carcinoma (IV, B).
- ▶ More extensive procedures should only be performed if required to achieve free surgical margins (IV, B).

Medically unfit patients

It is rare for patients to be unfit for surgery, but medical co-morbidities, which increasingly include morbid obesity, can preclude surgery due to high operative and peri-operative risks. Ideally, assessment should be undertaken in a center with specialist anesthetic experience in managing these high-risk patients. Definitive radiotherapy with brachytherapy, external beam radiation therapy (EBRT) or the combination of both modalities can be considered.^{258–262}

Recommendations

- ▶ Medical contra-indications to the standard surgical management by minimally invasive surgery are rare. Vaginal hysterectomy, with bilateral salpingo-oophorectomy if feasible, can be considered in patients unfit for the recommended standard surgical therapy (IV, C).
- ▶ Definitive radiotherapy can be considered for primary tumors where surgery is contra-indicated for medical reasons:
 - The combination of EBRT and brachytherapy should be used for high-grade tumors and/or deep myometrial invasion (II, B).
 - For low-grade tumors, brachytherapy alone can be considered (II, B).
 - In medically unfit patients unsuitable for curative surgery or radiotherapy, systemic treatment (including hormonal therapy) can be considered (IV, B).

Fertility preservation

Work-up for fertility preservation treatments

Fertility-sparing treatments should be considered in patients with atypical hyperplasia/endometrioid intra-epithelial neoplasia (AH/EIN) or grade 1 endometrioid carcinoma without myometrial invasion.^{263–269} There are very few published data on patients with stage IA grade 2 endometrioid carcinoma without myometrial invasion who received fertility-sparing treatment with combined oral medroxyprogesterone acetate/levonorgestrel intrauterine system.²⁷⁰ Although results are encouraging, this treatment should only be considered by experienced gynecological oncologists using well-defined protocols with detailed patient information and close follow-up.

Hysteroscopic biopsy is suggested, based on its higher agreement with the final diagnosis compared with dilatation and curettage.^{271 272} Although hysteroscopy seems to be associated with a higher rate of positive peritoneal cytology, it seems not to have a negative impact on survival.²⁷³ Expert vaginal ultrasound examination can be used instead of pelvic MRI. Its high diagnostic performance allows the detection of myometrial invasion and cervical

stromal invasion with respect to final pathologic examination. Ultrasound should be performed by an expert sonographer (a practitioner who spends a significant part of her/his time undertaking ultrasound examinations in gynecology and gynecologic oncology and has fulfilled the minimum training requirements for level 3 following the recommendations of the European Federation of Societies for Ultrasound in Medicine and Biology).²⁷⁴

There is currently a lack of high-quality evidence regarding the correlation between weight loss and reduction of risk of recurrence/increased survival in patients with endometrial carcinoma, especially with respect to fertility-sparing treatment.²⁷⁵ Diabetes mellitus does not seem to affect the outcome of conservative treatment in women with AH/EIN or early endometrial carcinoma.²⁷⁶ Conversely, the use of metformin seems associated with an improvement in overall survival for patients with endometrial carcinoma and a reduced risk of cancer relapse.²⁷⁷ In addition, metformin is associated with improvement in the overall survival of patients with endometrial carcinoma with diabetes.

Recommendations

- ▶ Patients who are candidates for fertility-preserving treatment must be referred to specialized centers. Fertility-sparing treatment should be considered only in patients with AH/EIN or grade 1 endometrioid endometrial carcinoma without myometrial invasion and without genetic risk factors (V, A).
- ▶ In these patients, endometrial biopsy, preferably through hysteroscopy, must be performed (III, A).
- ▶ AH/EIN or grade 1 endometrioid endometrial carcinoma must be confirmed/diagnosed by a pathologist experienced in gynecological pathology (V, A).
- ▶ Radiologic imaging to assess the extension of the disease must be performed. An expert ultrasound examination can substitute pelvic MRI scan (III, B).
- ▶ Patients must be informed that fertility-sparing treatment is not a standard treatment. Only patients who strongly desire to preserve fertility should be treated conservatively. Patients must be willing to accept close follow-up and be informed of the need for future hysterectomy in case of failure of treatment and/or after pregnancies (V, A).

Management and follow-up for fertility preservation

To date, there are no available randomized controlled trials comparing different methods of conservative treatment in women with AH/EIN or presumed stage IA grade 1 endometrioid carcinoma. Existing data suggest that patients who received hysteroscopic resection followed by progestin therapy achieve the highest complete remission rate compared with other existing fertility-preserving treatments.^{263–269 278–295} Intrauterine progestin therapy such as levonorgestrel-releasing intrauterine system combined with gonadotropin-release hormone receptor agonist/progestin have a satisfactory pregnancy rate and low recurrence rate. Patients who received oral progestin only might be more likely to recur and have more systemic adverse effects.

Recommendations

- ▶ All patients should be evaluated before and after the fertility-sparing treatment at a fertility clinic (IV, C).

- ▶ Hysteroscopic resection prior to progestin therapy can be considered (III, B).
- ▶ Medroxyprogesterone acetate (400–600 mg/day) or megestrol acetate (160–320 mg/day) is the recommended treatment. Treatment with levonorgestrel intrauterine device in combination with oral progestins with or without gonadotropin-releasing hormone analogs can also be considered (IV, B).
- ▶ In order to assess response, hysteroscopic guided biopsy and imaging at 3–4 and 6 months must be performed. If no response is achieved after 6 months, standard surgical treatment is recommended (IV, B).
- ▶ Continuous hormonal treatment should be considered in responders who wish to delay pregnancy (IV, B).
- ▶ Strict surveillance is recommended every 6 months with TVUS and physical examination. During follow-up, hysteroscopic and endometrial biopsy should be performed only in case of abnormal uterine bleeding or atypical ultrasound findings (IV, B).
- ▶ Fertility-sparing treatment can be considered for intrauterine recurrences only in highly selected cases under strict surveillance (IV, C).
- ▶ Hysterectomy and bilateral salpingo-oophorectomy is recommended after childbearing due to a high recurrence rate. Preservation of the ovaries can be considered depending on age and genetic risk factors (IV, B).

Synchronous presentation of low-grade endometrioid endometrial and ovarian carcinomas

Adnexal involvement by endometrial carcinoma is currently a parameter important in FIGO staging and has an impact on overall survival rate.²⁹⁶ It was shown that patients with simultaneous involvement of the endometrium and ovary by low-grade endometrioid carcinoma had a favorable outcome. This suggested that they were synchronous primary tumors rather than metastatic sites. Several criteria have been used in the past to distinguish between endometrial carcinoma with ovarian metastasis and synchronous primary tumors.^{297 298} However, these were not easy to apply.

Recent studies have shown that, for low-grade endometrioid carcinomas, there is a clonal relationship between endometrial and ovarian carcinomas in the vast majority of cases, indicating that the carcinoma arises in the endometrium and extends secondarily to the ovary.^{299 300} In the most recent edition of WHO (2020) it is mentioned that patients with clonally related low-grade endometrioid carcinomas should be managed without adjuvant treatment (as if they were two independent primaries) when fulfilling the following criteria: (1) low-grade endometrioid morphology, (2) no more than superficial myometrial invasion, (3) absence of LVSI, and (4) absence of additional metastases.^{33 301}

Recommendation

- ▶ If all WHO 2020 criteria mentioned above are met and the ovarian carcinoma is pT1a, no adjuvant treatment is recommended (III, B).

ADJUVANT TREATMENT

Adjuvant treatment recommendations for endometrial carcinoma strongly depend on the prognostic risk group (see [Table 2](#) for

Joint statement

definitions of the prognostic risk groups with and without known molecular classification).

Low risk

For patients with low-risk endometrial carcinoma, no adjuvant treatment is recommended based on data from multiple randomized trials.^{302–305} For patients with stage I–II *POLE*mut endometrial carcinomas, no adjuvant treatment seems justifiable based on the data from independent series showing very few recurrences and also in cases of observation.^{21 25} For stage III patients, however, there are only indirect data to support this, as all cases with advanced disease had adjuvant treatment. In the molecular analysis of the PORTEC-3 trial of high-risk endometrial carcinoma, those with *POLE*mut endometrioid carcinoma had an excellent outcome in both arms.²² However, both trial arms included EBRT. Prospective registration (preferably in national or international studies) of *POLE*mut endometrial carcinoma cases with treatment and outcome data is strongly recommended.

Recommendations

- ▶ For patients with low-risk endometrial carcinoma, no adjuvant treatment is recommended (I, A).
- ▶ When molecular classification is known:
 - For patients with endometrial carcinoma stage I–II, low-risk based on pathogenic *POLE*-mutation, omission of adjuvant treatment should be considered (III, A).
 - For the rare patients with endometrial carcinoma stage III–IVA and pathogenic *POLE*-mutation, there are no outcome data with the omission of the adjuvant treatment. Prospective registration is recommended (IV, C).

Intermediate risk

Adjuvant brachytherapy provides excellent vaginal control and high survival rates, similar to those after adjuvant EBRT in this intermediate-risk population, as shown in large randomized trials, particularly the PORTEC-2 trial and Swedish trial.^{306–314} It was also shown that only the small minority of patients with higher risk based on substantial LVSI, p53abn, or L1CAM overexpression had a slightly higher risk of pelvic recurrence with vaginal brachytherapy than those who had EBRT. Therefore, the intermediate-risk category only includes those with none or only focal LVSI and no p53abn. In a Danish population study it was confirmed that the risk of locoregional relapse was higher (about 14%) with omission of vaginal brachytherapy, but that overall survival was not different due to treatment of relapse.³¹⁵ Therefore, no adjuvant treatment is an option in this group, especially for patients aged <60 years who have a lower risk of relapse.

MMRd and, especially, NSMP cancers form the majority of endometrioid carcinomas and have an intermediate prognosis, in between *POLE*mut (excellent prognosis) and p53abn carcinomas (unfavorable prognosis). Findings of prior large randomized trials in high–intermediate-risk endometrial carcinoma are therefore mainly applicable to MMRd and NSMP endometrioid carcinomas in this intermediate-risk category.

It has to be stressed that p53abn carcinomas restricted to a polyp or without myometrial invasion were not included in the randomized trials and the value of chemotherapy and of EBRT are uncertain. Since the studies mentioned above did not include and/

or did not address non-endometrioid (and/or p53abn) carcinomas without myometrial invasion, there are very few specific available data on the best treatment for stage IA non-endometrioid carcinomas (serous, clear cell, undifferentiated carcinoma, carcinosarcoma, mixed) without myometrial invasion. Some case series and a recent analysis using the US National Cancer Data Base suggest that adjuvant chemotherapy (with or without vaginal brachytherapy) might improve survival, while other reports showed good outcomes with vaginal brachytherapy only.³⁰⁶ Therefore, these carcinomas have been grouped in the intermediate-risk category and adjuvant therapy should be discussed on a case-by-case basis until more prospective data are available.

Recommendations

- ▶ Adjuvant brachytherapy can be recommended to decrease vaginal recurrence (I, A).
- ▶ Omission of adjuvant brachytherapy can be considered (III, C), especially for patients aged <60 years (II, A).
- ▶ When molecular classification is known, *POLE*mut and p53abn with myometrial invasion have specific recommendations (see respective recommendations for low- and high-risk).
- ▶ For p53abn carcinomas restricted to a polyp or without myometrial invasion, adjuvant therapy is generally not recommended (III, C).

High–intermediate risk (pN0 after lymph node staging)

The definition of high–intermediate risk has changed in comparison with the ESMO-ESGO-ESTRO consensus conference. In the current prognostic risk group classification (see Table 2), stage IA endometrioid carcinomas are only included if there is substantial LVSI.^{3–5} This high–intermediate-risk group also includes stage IB low-grade endometrioid with substantial LVSI, and stage IB high-grade endometrioid carcinomas regardless of LVSI, and stage II endometrioid carcinomas. In view of the higher risk of recurrence in this newly classified group (even with negative nodes), adjuvant brachytherapy can be recommended to decrease vaginal recurrence. In the case of substantial LVSI and/or stage II, EBRT can be considered as it has been shown to reduce the risk of pelvic and para-aortic nodal relapse.³¹⁶

In two older randomized controlled trials^{317 318} there was no difference between adjuvant chemotherapy alone and EBRT alone in recurrence-free and overall survival. In the NSGO/EORTC trial and the PORTEC-3 trials, the combination of chemotherapy and radiotherapy seemed to provide better recurrence-free and overall survival outcomes respectively compared with radiotherapy alone.^{319 320} The GOG-249 trial did not find benefit in recurrence-free or overall survival from three cycles of chemotherapy with brachytherapy compared with EBRT alone.³¹⁶ Molecular analysis of PORTEC-3 trial tissues suggested no benefit of chemotherapy for MMRd carcinomas.^{320 321} Omission of adjuvant treatment is an option and this should be considered only when close follow-up is guaranteed to ensure detection and prompt treatment of recurrence at an early stage.

Recommendations

- ▶ Adjuvant brachytherapy can be recommended to decrease vaginal recurrence (II, B).

- ▶ EBRT can be considered for substantial LVSI and for stage II (I, B).
- ▶ Adjuvant chemotherapy can be considered, especially for high-grade and/or substantial LVSI (II, C).
- ▶ Omission of any adjuvant treatment is an option (IV, C).
- ▶ When molecular classification is known, *POLE*mut and p53abn have specific recommendations (see respective recommendations for low- and high-risk).

High-intermediate risk cNO/pNx (lymph node staging not performed)

In view of the recent randomized trials GOG-249 (for stage I and II endometrial carcinomas with high-risk factors or serous or clear cell histology), the PORTEC-3 trial and the older GOG-99 trial, adjuvant EBRT is recommended in case of substantial LVSI or stage II.^{302 316 319 320 322} Additional chemotherapy can be considered, especially for high-grade carcinomas, based on the PORTEC-3 trial, but the question remains whether the benefit outweighs the toxicity for stage I-II endometrioid carcinomas, and multi-disciplinary shared decision-making is needed.³²⁰ Molecular analysis of PORTEC-3 trial tissues suggested no benefit of chemotherapy for MMRd carcinomas.^{320 321} Adjuvant brachytherapy alone can be considered for LVSI negative cases and for stage II grade 1 disease.

Recommendations

- ▶ Adjuvant EBRT is recommended, especially for substantial LVSI and/or for stage II (I, A).
- ▶ Additional adjuvant chemotherapy can be considered, especially for high-grade and/or substantial LVSI (II, B).
- ▶ Adjuvant brachytherapy alone can be considered for high-grade LVSI negative and for stage II grade 1 endometrioid carcinomas (II, B).
- ▶ When molecular classification is known, *POLE*mut and p53abn have specific recommendations (see respective recommendations for low- and high-risk).

High risk

The risk category changes also have a substantial impact on this category. Some carcinomas designated as high risk in the ESMO-ESGO-ESTRO consensus conference are not included anymore in the high-risk sub-group in these ESGO-ESTRO-ESP guidelines.³⁻⁵ High-risk carcinomas are now either stage III-IVA without residual disease or stage I-IVA p53abn or non-endometrioid carcinomas without residual disease with myometrial invasion (for specifics see Table 2).

In 2019 the updated results of the PORTEC-3 trial, with a longer median follow-up of 72 months and with 75% of participants having reached 5 years of follow-up, were published.³²³ In this trial comparing combined chemotherapy and radiotherapy (two cycles of cisplatin during radiotherapy followed by four cycles of carboplatin-paclitaxel) with radiotherapy alone, a statistically significant 5% overall survival benefit at 5 years and a 7% failure-free survival benefit was seen in the combined therapy group compared with radiotherapy alone. The greatest overall survival difference was seen in stage III carcinomas and in serous carcinomas regardless of stage. The GOG-258 trial compared the same chemotherapy-radiotherapy schedule used in PORTEC-3 with six cycles of carboplatin-paclitaxel chemotherapy alone and found

overlapping relapse-free and overall survival rates.³²⁴ However, the chemotherapy alone arm had significantly higher rates of pelvic and peri-aortic nodal relapse. Therefore, chemotherapy alone is an alternative option based on the GOG-258 results for stage III-IV disease. The final analysis of the GOG-249 trial highlighted that a post-operative adjuvant strategy of vaginal cuff brachytherapy followed by three cycles of paclitaxel and carboplatin chemotherapy did not significantly increase 5-year recurrence-free survival or 5-year overall survival compared with pelvic radiotherapy.³²⁵ Vaginal and distant recurrence rates were similar between arms. However, pelvic or para-aortic nodal recurrences were significantly less common with pelvic radiotherapy. The older pooled analysis of the NSGO-EORTC and MANGO-ILIADE trials used sequential chemotherapy and radiotherapy (either sequence) and reported significantly longer recurrence-free survival compared with radiotherapy alone.³¹⁹ Multiple retrospective studies indicated a survival benefit in patients with advanced stage endometrial carcinoma treated with post-operative combined treatment including radiotherapy and chemotherapy, delivered by either the sandwich or sequential method, compared with radiotherapy alone or chemotherapy alone.³²⁶⁻³⁴⁴

The benefit of added chemotherapy is unclear for patients with stage I-II clear cell carcinomas. These have often been included with serous as 'non-endometrioid carcinomas'. Of note, in the PORTEC-3 trial it was specifically in those with serous histology that a significant benefit of added chemotherapy was seen.³²³ However, this was not observed in the NSGO-EORTC and MANGO-LEADE trials. Extended field radiotherapy is used in the case of involved para-aortic nodes or involvement of high common iliac nodes, both with or without chemotherapy. The combination of extended field radiotherapy with chemotherapy using modern intensity-modulated radiation therapy/volumetric modulated arc therapy (IMRT/VMAT) techniques has been shown feasible in the PORTEC-3 and GOG-258 trials. An additional brachytherapy boost can be considered, especially for substantial LVSI, endocervical stromal invasion, and/or stage IIIB-IIIC.

MMRd and NSMP carcinomas are included in the high-risk category if stage III-IVA with no residual disease. The p53abn carcinomas can be of endometrioid, serous, undifferentiated, and clear cell histologic type, but all consistently show a poor outcome and should therefore be regarded as high risk. Based on the current data, it is more difficult to draw conclusions regarding carcinosarcomas and undifferentiated carcinomas that are NSMP endometrial carcinomas due to the lack of large series. For clear cell carcinomas, the available data suggest some prognostic information may lie in the molecular classification. About 40-50% of clear cell carcinomas are p53abn. While serous carcinomas in the PORTEC-3 trial had an unfavorable outcome and significant benefit of added adjuvant chemotherapy, those with clear cell carcinomas seemed to have an outcome similar to high-grade carcinomas in general and were more favorable if not p53abn.^{321 323} The findings of the randomized trials for endometrioid carcinomas cited above are therefore largely applicable to stage III MMRd and NSMP carcinomas and to stage I-III p53abn carcinomas. This was also seen in the molecular analysis of the PORTEC-3 trial, which showed a statistically significant survival advantage for p53abn carcinomas with combined therapy for stage I-III. In contrast, *POLE*mut carcinomas had almost no recurrences in both arms. There was no clear

Joint statement

benefit of added chemotherapy for MMRd, while the NSMP carcinomas had some benefit of added chemotherapy especially in case of stage III. Prospective evaluation of the molecular characteristics in randomized trials is highly recommended.

Recommendations

- ▶ EBRT with concurrent and adjuvant chemotherapy (I, A) or alternatively sequential chemotherapy and radiotherapy is recommended (I, B).
- ▶ Chemotherapy alone is an alternative option (I, B).
- ▶ Carcinosarcomas should be treated as high-risk carcinomas (not as sarcomas) (IV, B).
- ▶ When the molecular classification is known, p53abn carcinomas without myometrial invasion and *POLEmut* have specific recommendations (see respective recommendations for low- and intermediate-risk) (III, C).

ADVANCED DISEASE

Surgery for clinically overt stage III and IV disease

In stage III and IV endometrial carcinoma (including carcinosarcoma), maximal cytoreduction should be considered only if macroscopic complete resection is feasible with acceptable morbidity.^{345–350} Surgery should be performed in a specialized center. Pre-operative complete staging and multi-disciplinary discussion within a tumor board should be performed. Suspicious enlarged lymph nodes should be resected if complete resection is possible.^{351 352} A full systematic pelvic and para-aortic lymphadenectomy of non-suspicious lymph nodes should not be performed because there is no evidence of a therapeutic impact. If upfront surgery is not feasible or acceptable and therefore primary systemic therapy is given, delayed surgery can be considered in case of a meaningful response to chemotherapy.^{353–360}

Recommendations

- ▶ In stage III and IV endometrial carcinoma (including carcinosarcoma), surgical tumor debulking including enlarged lymph nodes should be considered when complete macroscopic resection is feasible with an acceptable morbidity and quality of life profile, following full pre-operative staging and discussion by a multi-disciplinary team (IV, B).
- ▶ Primary systemic therapy should be used if upfront surgery is not feasible or acceptable (IV, A).
- ▶ In cases of a good response to systemic therapy, delayed surgery can be considered (IV, C).
- ▶ Only enlarged lymph nodes should be resected. Systematic lymphadenectomy is not recommended (IV, B).

Unresectable primary tumor due to local extent of disease

For patients presenting with unresectable locally advanced disease and no evidence of multiple distant metastases, treatment options include definitive radiotherapy or neoadjuvant chemotherapy followed by surgery or definitive radiotherapy, depending on response.^{261 354–356 361} Definitive radiotherapy comprises EBRT to the pelvis followed by image-guided brachytherapy. Concurrent chemotherapy may be considered to enhance the radiation effect. Brachytherapy should boost sites of macroscopic disease in the uterus, parametrium, or vagina using the ESTRO principles. Adjuvant chemotherapy should also be considered following primary

local treatment (surgery or radiotherapy) to reduce the risk of distant metastases.

Recommendations

- ▶ For unresectable tumors, multi-disciplinary team discussion should consider definitive radiotherapy with EBRT and intra-uterine brachytherapy, or neoadjuvant chemotherapy prior to surgical resection or definitive radiotherapy, depending on response (IV, C).
- ▶ Image-guided brachytherapy is recommended to boost intra-uterine, parametrial, or vaginal disease (IV, A).
- ▶ Chemotherapy should be considered after definitive radiotherapy (IV, B).

Residual pelvic or para-aortic lymph nodes following surgery

Residual lymph node disease can be treated with EBRT using an integrated or sequential boost to escalate the nodal dose. An IMRT technique reduces the risk of toxicity to surrounding tissue.³⁶² Adjuvant chemotherapy reduces the risk of distant metastases for patients with lymph node involvement.^{320 323 324}

Recommendations

- ▶ Residual lymph node disease should be treated with a combination of chemotherapy and EBRT (III, B) or chemotherapy alone (IV, B).
- ▶ EBRT should be delivered to pelvis and para-aortic nodes with dose escalation to involved nodes using an integrated or sequential boost (IV, B).

Residual pelvic disease (positive resection margin, vaginal disease, pelvic side wall disease)

Patients with residual pelvic disease following surgery have a high risk of both local and distant recurrence. Radiotherapy can achieve long-term local control while chemotherapy reduces the risk of distant metastases. An individualized approach with either (chemo)-radiotherapy to the pelvis followed by chemotherapy or adjuvant chemotherapy followed by radiotherapy to the pelvis±para-aortic nodes should be considered.

Recommendation

- ▶ An individualized approach with either radiotherapy or chemotherapy or a combination of both modalities should be considered by a multi-disciplinary team (V, B).

RECURRENT DISEASE

Radiotherapy naïve patients

Treatment of patients with recurrent endometrial carcinoma involves a multi-disciplinary approach with surgery, radiotherapy, and/or systemic therapy depending on the fitness and wishes of the patient, the tumor dissemination patterns, and prior treatment. A decision about surgery needs to take account of patient morbidity and wishes, available non-surgical treatments, and resources. The interval between primary treatment and recurrence should also be taken into consideration. Patients with recurrent disease, including resectable peritoneal and lymph node relapse, should be considered for surgery only if it is anticipated that complete resection of macroscopic disease can be achieved with a reasonable morbidity profile.^{363–369} The extent of the operation will depend on the degree of tumor dissemination pattern.

Locoregional recurrence of endometrial carcinoma is rare. With the advent of modern image-guided radiation therapy, including IMRT and image-guided adaptive brachytherapy, radiotherapy has become the treatment of choice in previously non-irradiated patients with isolated vaginal recurrence or locoregional recurrence.^{363 364 370–379} Consideration should be given to remove solitary easily accessible vaginal relapses, for better local symptom control prior to radiotherapy.

Recommendations

- ▶ Patients with recurrent disease (including peritoneal and lymph node relapse) should be considered for surgery only if it is anticipated that complete removal of macroscopic disease can be achieved with acceptable morbidity. Systemic and/or radiation therapy should be considered post-operatively depending on the extent and pattern of relapse and the amount of residual disease (IV, C).
- ▶ In selected cases, palliative surgery can be performed to alleviate symptoms (eg, bleeding, fistula, bowel obstruction) (IV, B).
- ▶ For locoregional recurrence, the preferred primary therapy should be EBRT±chemotherapy with brachytherapy (IV, A).
- ▶ An easily accessible superficial vaginal tumor can be resected vaginally prior to radiotherapy (IV, C).
- ▶ For vaginal cuff recurrence:
 - Pelvic EBRT+intracavitary (±interstitial) image-guided brachytherapy is recommended (IV, A).
 - In case of superficial tumors, intracavitary brachytherapy alone can be considered (IV, A).
- ▶ Systemic treatment can be considered before or after radiotherapy (IV, C).

Radiotherapy pre-treated patients with locoregional recurrence

In patients who have previously received EBRT±brachytherapy, radical surgery with the intention of complete resection with clear margins should be considered in specialized centers after ruling out metastatic disease with modern imaging. Pelvic exenteration may be considered for central local relapse.^{349 380 381} Otherwise, further radiation should be considered as radical therapy with or without systemic therapy. Interstitial brachytherapy (low-dose rate or high-dose rate) as the sole modality of treatment or combined with EBRT can result in high local control over 1–5 years.^{374 375 382 383} Other techniques like permanent seed implant or post-operative electron irradiation, protons and stereotactic body radiotherapy may be recommended in highly selected patients.^{384–386} The appropriate dose for each case needs to be individualized. Some low-dose rate data suggest improved outcomes with doses >50 Gy. The high-dose rate data are more varied, suggesting improved local control with doses >40 Gy. In general, a longer time interval between the first and second course of radiation as well as recurrences <2–4 cm tend to have improved outcomes. Multi-disciplinary management is critical to develop individualized plans and to clearly communicate potential side effects and expected treatment outcomes.

Recommendations

- ▶ In patients with a history of previous radiation, radical surgery, including exenteration, should be considered when the intention is complete resection with clear margins (IV, B).

- ▶ Additional options to consider include intra-operative electron radiation therapy or other forms of radiation therapy (IV, C).
- ▶ If surgery is not feasible, radical re-irradiation options include stereotactic body radiotherapy targeting the recurrence, permanent seed implants, or proton therapy. In selected cases, limited volume re-irradiation with EBRT and brachytherapy boost may be an option (especially if longer interval from the first irradiation) (IV, C).
- ▶ In patients who only had previous brachytherapy, EBRT+brachytherapy boost is recommended (IV, C).
- ▶ In patients where re-irradiation with EBRT is not an option, image-guided interstitial brachytherapy only is recommended (may improve outcome) (IV, C).

Oligometastatic recurrent disease

Oligometastases is a disease concept that is defined by a state of limited metastatic tumors for which local ablative therapy could be curative. It refers in general to cancer patients with 1–5 metastases or recurrences.^{387–389} In recent years the concept of oligometastatic relapse has evolved and has led to a change in the approach to treatment. A prolonged disease-free interval and perhaps even cure may be achieved in some situations where the primary cancer site (if still present) is controlled and metastatic sites are ablated (surgically or with radiation).^{390–393} Multi-disciplinary management is critical to develop individualized plans and to communicate potential side effects and expected treatment outcomes. The additional benefit of chemotherapy is uncertain.

Recommendations

- ▶ Patients with oligometastatic disease should be considered for radical local therapy (IV, B).
- ▶ Treatment options include (IV, B):
 - Surgery
 - Radiation therapy including stereotactic radiotherapy
 - Local ablating techniques
- ▶ The additional benefit of chemotherapy is uncertain (IV, B).

Systemic treatment for recurrent disease

Hormonal treatment results in a response rate of up to 55% in advanced/recurrent endometrial carcinoma.³⁹⁴ Low-grade, slowly progressing, hormone receptor-positive tumors appear to gain the greatest benefit from treatment; however, clinical benefit has also been observed in patients with hormone receptor-negative tumors.³⁹⁵ Progestogens are generally recommended.³⁹⁵ Alternative options include aromatase inhibitors, tamoxifen, and fulvestrant. In the PARAGON trial a response rate of 7% and a clinical benefit rate of 44% was reported with anastrozole in a cohort of 82 patients with recurrent, receptor positive, endometrial carcinoma.³⁹⁶ A single-arm phase II trial demonstrated a high response rate and clinical benefit rate with the combination of letrozole and everolimus.³⁹⁷ Confirmation of hormone receptor status by biopsy should be considered at the time of recurrence because of a potential change in hormone receptor expression between primary tumor and recurrence. In patients undergoing hormonal therapy, the risk of thrombo-embolic events needs to be taken into account. Prophylaxis with low molecular weight heparin should be considered in patients at high risk for thrombosis and be given according to local guidelines. There are no universally agreed recommendations to

Joint statement

predict a response to hormonal therapy in endometrial carcinoma based on estrogen and progesterone receptor immunohistochemical status. Some of the following should be taken into account: (1) a wide range of hormonal agents are used, including medroxyprogesterone acetate and synthetic progestational agents, luteinizing hormone releasing hormone antagonists, tamoxifen, and new generations of selective estrogen receptor modulators; each has a different molecular action and may therefore have different activity; (2) receptor-negative status is not an absolute contra-indication to hormone treatment; (3) in some reports, response rates to various hormonal treatments for patients with endometrial carcinoma are higher for those with progesterone receptor expression; (4) the methodology for assessing and scoring hormone receptor expression in endometrial carcinoma is variable in the reported series; (5) assessment of estrogen and progesterone receptor status in the primary tumor may not reflect the status in the recurrent or metastatic tumor and thus a biopsy of recurrent or metastatic carcinomas for hormone receptor analysis may be helpful; (6) from a pragmatic viewpoint, it seems reasonable to interpret a carcinoma as receptor positive when immunoreactivity for estrogen receptor or progesterone receptors is found in more than 1% of carcinoma cells, until stronger validated scientific evidence is provided.

The combination of carboplatin and paclitaxel is the standard chemotherapy treatment of advanced/recurrent endometrial carcinoma based on a randomized phase 3 trial comparing carboplatin-paclitaxel versus carboplatin-paclitaxel-anthracyclines that reported overlapping progression-free survival and overall survival between the two arms but an increased toxicity for the triple combination.³⁹⁸ No standard treatment has been identified as second-line therapy; a response rate of about 10–15% has been seen among all the available treatment options. Thus, enrollment of patients in clinical trials is strongly encouraged. Weekly paclitaxel and anthracyclines (including pegylated liposomal doxorubicin when available) are considered to be active drugs. The re-introduction of carboplatin may be considered after a prolonged interval from the last platinum treatment, based on the results of a single-center retrospective series in patients treated with a median platinum-free interval of 25 (8–79) months. A response rate of 50% and median progression-free and median overall survival of 10 and 27 months, respectively, was reported after platinum re-challenge.³⁹⁹

Several anti PD-1 and anti PD-L1 checkpoint inhibitors have been shown to have activity in endometrial carcinoma and thus far pembrolizumab has been approved by the Food and Drug Administration (FDA) based on the results of a phase 2 single arm trial for the treatment of MSI-high (MSI-H)/MMRd solid tumors that have progressed on conventional therapy.^{400 401} The combination of intravenous pembrolizumab and lenvatinib, an oral multi-receptor tyrosine kinase inhibitor, received FDA approval in October 2019 for the second-line systemic therapy of microsatellite-stable (ie, non-MSI-H/MMRd) endometrial carcinoma based on the results of a phase 2 single-arm trial reporting 36% response rate in this population, including significant activity in those with serous carcinoma.^{402 403} No phase 3 randomized data are yet available.

Approximately 30% of uterine serous carcinomas show HER2/neu over-expression. A small randomized phase 2 trial of paclitaxel and carboplatin with or without trastuzumab in HER2/neu positive disease showed a 4.6 month increase in median progression-free survival.⁴⁰⁴ Anti-angiogenic agents and PI3kinase/mTor and MEK

inhibitors also have demonstrated activity but secure evidence of benefit is inconclusive due to the limited sample size of the trials, inconsistency of results, and the low therapeutic index of the drugs, suggesting further investigations in well-designed and properly powered molecularly driven randomized trials are warranted.^{405–416}

Recommendations

- ▶ Hormone therapy is the preferred front-line systemic therapy for patients with low-grade carcinomas without rapidly progressive disease (II, A).
- ▶ Progestogens (medroxyprogesterone acetate 200 (–300) mg and megestrol acetate 160 mg) are recommended (III, A).
- ▶ Alternative options for hormonal therapies include aromatases inhibitors, tamoxifen, fulvestrant (III, C).
- ▶ The standard chemotherapy treatment is carboplatin AUC 5–6 + paclitaxel 175 mg/m² every 21 days for six cycles (I, A).
- ▶ There is no standard of care for second-line chemotherapy. Doxorubicin and paclitaxel are considered the most active therapies (IV, C).
- ▶ In patients with a long platinum-free interval, re-introduction of platinum can be considered (IV, C).
- ▶ Anti-PD1-based immune therapy with pembrolizumab could be considered for second-line therapy of MSI/MMRd carcinomas. The combination of pembrolizumab and the multi-tyrosine-kinase inhibitor lenvatinib could be considered for second-line treatment of microsatellite-stable carcinomas (III, B). However, its use may be limited due to regulatory approvals or reimbursement in different countries. Clinical trial participation should be offered to all patients with relapse disease (V, B).

Palliative radiotherapy

Historically, radiotherapy has been an efficient treatment to palliate bleeding and pain from pelvic disease or systemic metastases. This results in rapid pain relief and temporary cessation of bleeding in the majority of patients.⁴¹⁷

Recommendations

- ▶ Radiotherapy is indicated for palliation of symptoms related to pelvic or systemic disease (IV, A).
- ▶ Hypofractionated small volume EBRT can be used for treating primary disease in patients not fit for radical treatment (IV, B).

PRINCIPLES OF RADIOTHERAPY

The following sections present the general principles, the principles of adjuvant radiotherapy, of definitive treatment, and of radiotherapy for recurrent disease.^{258–261 307 362 372 377 418–423}

General principles

State-of-art techniques and radiotherapy dose are chosen based on clinical findings, pathology, and patient factors including co-morbidities. For complex treatments or rare cases, referral to a specialized center is recommended. Prospective assessment of toxicity is recommended. Patients should have counseling on pelvic care and general and sexual rehabilitation whenever appropriate.

Adjuvant radiotherapy

Radiotherapy should preferably commence within 6 (–8) weeks of surgery or be scheduled in relation to chemotherapy.

EBRT

IMRT/VMAT techniques are recommended because the more conformal dose distribution increases normal tissue-sparing compared with a four-field conventional or 3D-conformal plan.⁴²⁴

The clinical target volume (CTV) includes the pelvic nodes (external iliac, internal iliac, obturator, distal common iliac), parametria, and upper vagina. The upper common iliac and sub-aortic pre-sacral lymph nodes are included when there is cervical stromal involvement and/or pelvic lymph node involvement. The lymph node target volume may be extended to include the aortic bifurcation or para-aortic nodes, up to or just above the level of the renal vessels, depending on the location and number of positive lymph nodes, site of sentinel lymph nodes, and whether there is extrauterine primary tumor involvement. The CTV should be individualized when there is a positive resection margin, pelvic peritoneal disease, or vaginal involvement. Treatment with a comfortably full bladder reduces the volume of irradiated small bowel and bladder. The planning target volume (PTV) should account for potential internal motion, depending on the method of verification used during the course of treatment. Image-guided radiotherapy by repeated volumetric imaging with cone beam CT (and use of so-called library of plans or plan of the day techniques) may enable the use of smaller CTV-PTV margins to reduce normal tissue toxicity. The prescription dose is commonly 45–50.4 Gy in 25–28 fractions over 5–6 weeks. An integrated or sequential EBRT boost is given to residual lymph node disease, sites of extracapsular nodal spread, and positive lateral resection margins with a total dose of 55–60 Gy EQD_{2,10} for microscopic residual disease, or up to 66 Gy for macroscopic/bulky disease. Concurrent and adjuvant chemotherapy may be considered for stage III disease, serous histology and/or recurrent disease.

Vaginal brachytherapy

Vaginal examination is undertaken to ensure the vaginal cuff is healed and to assess the size and shape of the vagina to guide applicator selection. Usually a vaginal cylinder is used but other applicators can be used, depending on patient anatomy. The target volume is individually determined and is usually the upper third of the vagina to a depth of 5 mm (both superiorly and halfway along the active length). The high-dose rate brachytherapy dose is most commonly 21–24 Gy in 3–4 fractions to 0.5 cm from the applicator surface, or 8–11 Gy in 2–3 fractions when given as a boost following EBRT. A higher dose is required for treatment of residual disease or positive margins. Pulsed-dose rate brachytherapy can be used following EBRT to boost macroscopic residual disease with a dose of 15–25 Gy. The treatment planning options are to use a standard library plan for each applicator size and treatment length or to use image-guided adaptive brachytherapy. In institutions where image-guided adaptive brachytherapy is applied, imaging of the applicator with CT scan or MRI evaluates whether the applicator is in close apposition to the vaginal mucosa and close to organs at risk. This allows verification and calculation of cumulative doses, especially if vaginal brachytherapy is used as a boost after EBRT. Image-guided adaptive brachytherapy is strongly recommended when there is residual vaginal disease following surgery using similar principles to treatment for recurrent disease.

Definitive treatment

Definitive radiotherapy with EBRT, brachytherapy, or a combination of both is indicated for primary tumors where surgery is contraindicated for medical reasons. If patients are medically unfit for surgery, consider whether a long course of EBRT would be tolerated or, if not, a more hypofractionated approach could be used. Intrauterine brachytherapy as a sole treatment modality is used for low-grade early stage disease whereas the combination of EBRT and intra-cavitary brachytherapy is recommended for high-grade tumors and/or deep myometrial invasion. Specialist anesthetic review may be required to assess suitability for brachytherapy or whether brachytherapy could be applied with local anesthesia only. More advanced inoperable disease is treated with a combination of pelvic EBRT and intrauterine brachytherapy with or without concurrent platinum-based chemotherapy. EBRT is planned with at least three-dimensional (3D) conformal radiotherapy to ensure inclusion of the whole uterus. The preferred technique is intensity-modulated radiotherapy with adaptive image guidance to verify target volume coverage and to maximize normal tissue sparing. A highly conformal EBRT boost (with IMRT or stereotactic body radiotherapy) can be used to escalate the total dose to the tumor site in the uterus to at least 65 Gy if brachytherapy is not feasible.

Image-guided adaptive brachytherapy is recommended, preferably using MRI at the time of brachytherapy, in order to optimize tumor coverage and organ at risk doses. The brachytherapy applicator should consist of an intrauterine applicator (preferably a dedicated applicator with multiple channels for the larger uterus) and a vaginal component depending on the extent of any extrauterine disease. Interstitial applications may be required to achieve adequate coverage. In view of the rarity of definitive treatment for endometrial carcinoma, referral to a dedicated center is recommended. The tumor-related target volumes include the (residual) gross tumor volume on MRI (GTV-res) and the CTV is the whole uterus and any extrauterine sites of extension before EBRT. The treatment plan aims include a total dose (EQD_{2,10}) of at least 80 Gy to GTV-res, CTV D90 of about 48 Gy with brachytherapy alone, and 60–65 Gy with the combination of EBRT and brachytherapy.

Recurrent disease

Radiotherapy treatment for recurrent endometrial carcinoma depends on the site of disease and any previous treatment. It involves EBRT, brachytherapy, or a combination of both modalities. Concurrent or sequential chemotherapy may also be considered.

Radiation-naïve or previous brachytherapy only

Pelvic EBRT is used according to the guidelines above. Brachytherapy is used to boost recurrent disease in the vagina; in selected cases with superficial tumors brachytherapy alone can be considered. The brachytherapy applicator options include a vaginal cylinder or mold for superficial lesions whereas interstitial applicators can be used for bulkier tumors.

Image-guided adaptive brachytherapy is recommended, preferably using MRI at the time of brachytherapy, in order to optimize tumor coverage and organ at risk doses. When image-guided adaptive brachytherapy is used, the target volumes should be contoured according to the recent GEC-ESTRO recommendation for primary vaginal cancer, aiming for a total dose (EQD_{2,10}) of 80–85 Gy to CTV D90 with the combination of EBRT and image-guided

Joint statement

brachytherapy.⁴²² If brachytherapy is not feasible due to tumor location or topography, a sequential EBRT boost with conformal radiotherapy, IMRT, or stereotactic body radiotherapy is used to deliver a total GTV dose of at least 65 Gy EQD_{2,10}.

Re-irradiation

Re-irradiation is individualized according to the extent of disease, previous radiation fields, and time elapsed from the previous treatment. In general, recurrences with a longer disease-free interval as well as recurrences less than 2–4 cm tend to have improved outcomes. Ideally, this should be done in specialist centers with prospective collection of dosimetric and clinical data. The most common re-irradiation technique is intracavitary-interstitial brachytherapy, preferably image-guided with CT scan or MRI.⁴²¹ However, in selected cases EBRT, stereotactic body radiotherapy, proton or carbon ion therapy is an option, particularly for pelvic sidewall or lymph node disease. Organ at risk dose constraints should take into account prior radiotherapy treatment to derive cumulative doses. Some low-dose rate data suggest improved outcomes with doses more than 50 Gy. The high-dose rate data are more varied with some studies suggesting improved local control with doses more than 40 Gy EQD_{2,10}.

PRINCIPLES OF PATHOLOGIC EVALUATION

The following sections present the requirements for specimens submitted for pathologic evaluation including specimen grossing and sampling, for the pathology report, and the molecular classification.^{19 21 23 26 425 426} The sections are proposed in agreement with the recently published recommendations from the ISGyP and International Collaboration on Cancer Reporting, and WHO Classification of Tumors (5th edition).^{9 33 427–429}

Requirements for specimens submitted for pathologic evaluation

Patient information, previous cytology, histologic specimens, clinical and radiological data need to be included on the specimen request form, particularly if there is no electronic patient file. This needs to provide itemised details of biopsy and surgical specimen (type of hysterectomy, presence of ovaries and fallopian tubes, presence of lymph nodes, and designation of lymph node sites). Biopsies should be sent to the pathology department in a container with liquid fixative (10% neutral formalin is preferred). Surgical specimens should be either sent in a fixative or preferably fresh if there is a specific workflow for it and if the microbiological risk is controlled. This allows proper opening of the uterus and sampling a fresh tissue for research purposes.

Specimen grossing and sampling

All pathology reports should include a detailed section, code/block key on which the origin/designation of all tissue blocks should be recorded.

The specimen needs to be oriented, which means that the anterior and posterior walls of the uterus are identified using anatomic landmarks such as the peritoneal reflection and the round ligament/ovaries. All organs/structures received should be documented and their measurements and gross appearance recorded.

The uterus should be opened immediately on receipt in the pathology laboratory and placed in formalin within an hour of opening whenever possible. If the uterus is not immediately sent to a pathology laboratory, the uterine cavity needs to be opened technically correctly to guarantee proper fixation. The uterus is preferably opened along the lateral uterine walls (3 and 9 o'clock), although 12 and 6 o'clock sectioning may be acceptable.

The pathology laboratory personnel and/or pathologists should manage the requests for fresh tissue for banking and/or investigational protocols and this task should be completed as soon as the specimen is received in the pathology laboratory.

Inking of peritoneal and/or non-peritoneal surfaces is recommended in hysterectomy specimens and is mandatory in radical hysterectomy specimens in which the parametrium and vaginal cuff are present.

At least the largest dimension of the tumor must be provided, although providing three dimensions is recommended. Horizontal/transverse sectioning is recommended. Sampling one section per centimeter of the largest tumor dimension is recommended.

In case of pre-operative endometrial sampling with a malignant diagnosis and no visible lesion on gross examination or a history of atypical endometrial hyperplasia/EIN, the entire endometrium and adjacent inner myometrium should be submitted for microscopic examination. The same applies to hysterectomy specimens that have been obtained for other reasons (leiomyomas, adenomyosis, etc) when the endometrium is grossly inconspicuous but endometrial carcinoma or atypical endometrial hyperplasia/EIN are detected on the initial histological sections.

At least one full-thickness section of the uterine wall including serosa is required to show the deepest point of myometrial invasion.

The number of sections submitted should not be altered in the context of adenomyosis. However, in cases where the assessment of myometrial invasion is difficult because of tumor involving adenomyosis, taking additional sections of the uterine wall may be useful.

Whenever possible, the interface between the tumor and its surroundings should be submitted for microscopic examination. This facilitates the measurement of the depth of myometrial invasion and the identification of precursor lesions.

At least one representative section of non-neoplastic endometrium should be submitted for microscopic examination. In addition, any grossly identified endometrial lesions separate from the tumor should be submitted.

All gross endometrial abnormalities need to be submitted for microscopic examination in the hysterectomy specimen from patients with Lynch syndrome. In the absence of a gross lesion, the endometrium should be submitted *in toto*, including the lower uterine segment.

A minimum of two sections (one anterior, one posterior) should be submitted from the lower uterine segment.

Parametrial tissue/parametrium should be sampled before opening the uterus as this approach minimizes the chance of finding carryovers. All of the parametrial tissue/parametrium should be submitted for histologic examination. If macroscopic tumor is seen in the parametrial tissue/parametrium, the most proximal parametrial section should include the adjacent outer portion of the cervical wall.

The cervix should be left attached to the corpus during the gross examination of a hysterectomy specimen obtained for endometrial carcinoma. At least two full thickness sections (one anterior and one posterior) should be submitted from a grossly unremarkable cervix. At least two representative sections of tumor involving the cervix should be submitted when the cervix is grossly involved by endometrial carcinoma. These sections must include the full thickness of the cervical wall and the ectocervical or vaginal cuff margin.

Gross examination of a morcellated hysterectomy specimen requires special attention to identify any endometrial abnormality, although this may be extremely difficult to see in some cases. If such an abnormality is detected, the entire endometrial lesion and the adjacent myometrium should be submitted for microscopic examination. In addition, sampling of myometrial tissue containing any serosal surface should be undertaken. If the endometrium appears grossly unremarkable and the initial representative sections demonstrate the presence of atypical endometrial hyperplasia/EIN or endometrial carcinoma, careful re-grossing is required with the submission of all the visible endometrial lining and adjacent myometrium. If the morcellated specimen contains the uterine cervix, this should be sampled representatively.

Gross examination of the fallopian tube must be carefully undertaken and any areas with macroscopic abnormalities should be submitted for microscopic examination. If the fallopian tube is unremarkable, the entire tube should be submitted for microscopic examination using the sectioning and extensively examining the fimbriated end (according to the SEE-FIM protocol), particularly for serous carcinoma and carcinosarcoma, while only the fimbrial end should be submitted *in toto* in other scenarios using the guidelines of the SEE-FIM protocol, along representative cross-sections of the remainder of the fallopian tube.

Gross examination of the ovary must be carefully performed. In case of endometrial serous, clear cell carcinoma or carcinosarcoma, the entire ovary should be submitted after slicing it perpendicularly to its long axis at 2–3 mm intervals. If possible, the same protocol should be used for oophorectomy specimens accompanying hysterectomies for other endometrial carcinoma histotypes. Should the latter not be possible, at least two sections of each ovary should be submitted.

Omentectomy is part of the staging procedure of endometrial serous carcinoma, undifferentiated carcinoma, and carcinosarcoma. The gross appearance and measurement of the omentum should be provided. Omental tissue should be sliced at 0.5 cm intervals to detect small abnormalities. If the omentum is grossly positive, one or two representative sections are enough for microscopic evaluation, but if it is grossly negative, one representative section per 2 or 3 cm of maximal omental dimension or at least a total of four blocks of tissue should be submitted.

Lymph nodes from different anatomic sites should be sent in separate appropriately labeled specimen containers and handled separately. They should be carefully dissected from the adipose tissue. This can be done with a thorough visual examination and palpation. A small amount of adipose tissue should be left around larger lymph nodes to evaluate the presence or absence of extranodal extension. Lymph nodes up to 2 mm are totally embedded. If larger than 2 mm, parallel slices at 2–3 mm intervals perpendicular to the long axis of the node should be performed. All grossly unremarkable lymph node tissue should be submitted for microscopic

examination. The number of lymph nodes submitted per cassette and the way they have been submitted—for example, *in toto* if very small or sectioned—should be specified in the section code. With grossly positive lymph nodes, representative sections to demonstrate the largest size of tumor involvement as well as the surrounding adipose tissue should be submitted for microscopic examination and noted in the section code.

The description of the sentinel lymph node should include gross measurement and description of gross appearance including the presence of dye. The lymph node is sliced at 2–3 mm intervals perpendicular to its long axis. A small rim of adipose tissue should be left around the lymph node. The entire lymph node is submitted for microscopic examination in properly coded cassettes. Ultrastaging is encouraged (ie, additional recuts and/or IHC for keratin). At the present time there is no universal ultrastaging protocol.

Frozen section for intra-operative assessment is not encouraged for myometrial invasion assessment because of poor reproducibility and because it interferes with pre-analytical issues and the possibility of carryovers.

Report of pathology results (required items)

- ▶ Description of the specimen(s) submitted for histologic evaluation
- ▶ Attached anatomic structures
- ▶ Accompanying specimens
- ▶ Tumor type (WHO Classification of Tumors (5th edition))
- ▶ Tumor grade (FIGO and WHO Classification of Tumors (5th edition)). Endometrioid endometrial carcinoma is graded using FIGO grading criteria: grades 1, 2, and 3 tumors exhibit ≤5%, 6–50%, and >50% solid non-glandular (including cribriform), non-squamous growth. The presence of severe cytologic atypia in the majority of cells (>50%) increases the grade by one level, but serous carcinoma should be excluded in cases with nuclear atypia that is out of proportion to the architecture. Binary grading is recommended by the WHO Classification of Tumors (5th Edition) whereby grades 1–2 tumors are classified as low-grade and grade 3 tumors as high-grade.
- ▶ Absence or presence and depth of myometrial invasion should be reported in all endometrial carcinoma as 'none or less than half' OR 'half or more'. The measurement should be performed from the adjacent endometrial–myometrial interface.
- ▶ If myometrial invasion occurs from carcinoma within adenomyosis, the deepest myoinvasive point should be reported according to where this is located in the myometrium, and regardless of whether or not it arises from adenomyosis. In case of an exophytic tumor, the depth of myometrial invasion, and not tumor thickness, should be measured by identifying the adjacent endo–myometrial junction and by correlating with the macroscopic appearance. For tumors involving polyps, measurement of invasion is performed only if the tumor invades the underlying myometrium.
- ▶ LVSI should be unequivocal and reported as focal and extensive/substantial (five vessels or more). LVSI should not be included in assessment of myometrial invasion depth.
- ▶ Cervical stromal invasion: for the purposes of standard reporting, the uppermost endocervical mucinous gland identified in the section should be taken as the upper limit of the endocervix.

Joint statement

- ▶ Vaginal involvement.
- ▶ Uterine serosal involvement. Tumor infiltrating the full myometrial thickness and reaching sub-mesothelial fibro-connective tissue or the mesothelial layer should be reported as serosal involvement; tumor may or may not be present on the surface of the uterus; a desmoplastic response may or may not be present.
- ▶ Parametrial involvement.
- ▶ Adnexal involvement. Care should be taken to determine whether the ovarian involvement is considered to be metastatic or 'synchronous'. Synchronous low-grade endometrioid carcinomas of the endometrium and the ovary have been demonstrated mostly to be clonally related in the vast majority of cases. Their reported indolent behavior supports conservative management when the following criteria are met: (a) both tumors are low grade; (b) <50% myometrial invasion; (c) no involvement of any other site; (d) absence of extensive LVSI at any location. These parameters should be reported and included in a specific comment.
In cases of serous endometrial carcinoma with co-existing tubal intra-epithelial (mucosal) carcinoma, with or without stromal invasion, ancillary techniques should be undertaken to help define whether the Fallopian lesion is independent or metastatic. In cases of endometrioid endometrial carcinoma, a comment may be included on the unknown prognostic significance of this finding.
- ▶ Omental involvement.
- ▶ Peritoneal involvement.
- ▶ Lymph node status including sentinel lymph node status reports the total number of nodes found and the number of positive lymph nodes, and the presence of extranodal extension (list for all separate sites). Micrometastasis (>0.2 mm and up to 2 mm) are reported as pN1(mi). ITCs no greater than 0.2 mm in regional nodes should be reported as pN0 (i+).
- ▶ Pathologically proven distant metastases.
- ▶ Required ancillary techniques (IHC for p53, MSH-6 and PMS-2, complemented with MLH-1 and MSH-2, MLH-1 promoter methylation analysis in cases of MLH-1/PMS-2 decrease expression). Additional immunohistochemical markers may be important for pathologic diagnosis (PTEN, p16, ER, Napsin A, Racemase, Pax8, E-Cadherin) or prognosis (L1CAM).
- ▶ Provisional pathologic staging pre-tumor board/multi-disciplinary team meeting. The TNM staging system (Union for International Cancer Control and American Joint Committee on Cancer versions) for endometrioid carcinoma is largely concordant with the widely used FIGO system.

Report of pathology results (recommended items unrelated to stage and with limited supporting evidence)

- ▶ Tumor site.
- ▶ Tumor size.
- ▶ Percentages of different components of mixed carcinoma and in carcinosarcoma.
- ▶ Measurement of absolute depth of myometrial invasion, percentage of myometrium infiltrated by tumor, invasion of inner, middle, or outer one third of the myometrium, distance of myo-invasive tumor to serosal surface.
- ▶ Microcystic, elongated, fragmented pattern of invasion.

- ▶ Peritoneal cytology (if available).
Recommended ancillary investigations.

Molecular classification

The decision to use molecular classification in all endometrial carcinoma cases in the subset of high-grade or high-risk tumors or in none of the cases depends on the availability of resources and decision by the multi-disciplinary team of each center.

Molecular classification is recommended to be performed by the TCGA surrogate using the diagnostic algorithm provided by Vermij *et al.*²⁴ This diagnostic algorithm requires testing of three immunohistochemical markers (p53, MSH-6, PMS-2) and somatic mutation analysis of *POLE* (exons 9, 11, 13, 14). Guidance on the interpretation of pathogenicity of *POLE* variants is provided by Leon-Castillo *et al.*²⁶

Five categories of tumors are recognized: (1) ultramutated/with pathogenic *POLE* mutations; (2) hypermutated with MSI/MMRd (loss of MMR protein immunoreactivity); (3) high copy number/p53abn (p53 mutant immunoreactive pattern); (4) low copy number/NSMP (retained MMR protein immunoreactivity, and p53 wild-type immunoreactive pattern); (5) multiple classifier (any combination of markers included in the previous categories).

If available, molecular classification data should be integrated into conventional pathologic diagnosis. The report should include information regarding the methods used for IHC as well as for *POLE* mutation analysis. It should include information from the literature regarding the pathogenicity of each *POLE* mutation detected.²⁶

PSYCHO-ONCOLOGICAL SUPPORT FOR WOMEN WITH ENDOMETRIAL CARCINOMA

Endometrial carcinoma, even as a cancer with a relatively good prognosis, is a life-threatening disease. Treatment may produce significant toxicities which cause substantial short- and long-term side effects, functional loss in various behavioral and life domains as well as psychosocial distress. The patient and her caregivers may face major challenges in terms of coping and adjustment.

Therefore, continuous evaluation for psychological distress, sexual dysfunction, and psychiatric co-morbidity as well as identification of psychosocial needs are of major importance.⁴³⁰ The first step includes an early assessment and identification of the patient's distress.⁴³¹ There are several standardized and validated screening instruments available such as the Hospital Anxiety and Depression Scale or the easy to use Distress Thermometer.⁴³² Depending on the result of the diagnostic process, various interventions should be offered such as counseling, individual or group psychotherapy, psychoeducational interventions, art therapies, or relaxation techniques. For patients with a disease involving genital organs, cancer itself, surgical treatment and subsequent hormonal loss may impair sexual function. Therefore, discussion and treatment of sexual problems should be integrated as part of a holistic approach.

In order to empower patients to cope with physical and psychosocial long-term side effects of disease, treatment, and to preserve quality of life, they should receive a personalized survivorship care plan including information and education life style and prevention of secondary malignancies and other diseases. Contact with advocacy groups should be offered to all patients.

Author affiliations

- ¹Department of Gynecology and Obstetrics, Innsbruck Medical University, Innsbruck, Austria
- ²Evangelische Kliniken Essen-Mitte, Essen, Germany
- ³Department of Pathology, Hospital Universitari Arnau de Vilanova, University of Lleida, CIBERONC, Irbllleida, Spain
- ⁴Department of Pathology, Hospital Universitari de Bellvitge, University of Barcelona, Idibell, Spain
- ⁵Department of Gynecology and Obstetrics, Gynecologic Oncology, Leuven Cancer Institute, Catholic University Leuven, Leuven, Belgium
- ⁶Department of Obstetrics and Gynecology, First Faculty of Medicine, Charles University, General University Hospital in Prague, Prague, Czech Republic
- ⁷Department of Oncology, Rigshospitalet, Copenhagen University Hospital, Copenhagen, Denmark
- ⁸Department of Radiation Oncology, Medical Faculty of the University of Cologne, Cologne, Germany
- ⁹UCL Cancer Institute, University College, London, UK
- ¹⁰Department of Pathology, Leids Universitair Medisch Centrum, Leiden, Netherlands
- ¹¹Department of Radiation Oncology, Institut Gustave Roussy, Villejuif, France
- ¹²Division of Gynecologic Oncology, Fondazione Policlinico Universitario A Gemelli IRCCS, Rome, Italy
- ¹³Department of Gynaecologic Oncology, Imperial College London Faculty of Medicine, London, UK
- ¹⁴Department of Medical Oncology, Clinica Universidad de Navarra, Madrid, Spain
- ¹⁵Department of Pathology, Hospital Graz II, Graz, Austria
- ¹⁶School of Medicine, Johannes Kepler University Linz, Linz, Austria
- ¹⁷Department of Obstetrics and Gynecology, Innsbruck Medical University, Innsbruck, Austria
- ¹⁸Department of Surgery, Institut Gustave Roussy, Villejuif, France
- ¹⁹Department of Radiotherapy, Erasmus MC Cancer Institute, Rotterdam, Netherlands
- ²⁰Department of Medical Oncology, St James Hospital, Dublin, Ireland
- ²¹Department of Obstetrics and Gynecologic Oncology, University Hospital, Strasbourg, France
- ²²Histopathology and Molecular Diagnostics, Azienda Ospedaliero Universitaria Careggi, Florence, Italy
- ²³Department of Gynecology with Center for Oncological Surgery, Campus Virchow Klinikum, Charité—Universitätsmedizin Berlin, Corporate Member of Freie Universität Berlin, Humboldt-Universität zu Berlin and Berlin Institute of Health, Berlin, Germany
- ²⁴Department of Radiation Oncology, Comprehensive Cancer Center, Christian Doppler Laboratory for Medical Radiation Research for Radiation Oncology, Medical University of Vienna, Vienna, Austria
- ²⁵Department of Gynaecology, Royal Marsden Hospital, London, UK
- ²⁶Department of Medical Oncology, Amsterdam University Medical Centres, Amsterdam, Noord-Holland, Netherlands
- ²⁷Department of Gynecology and Obstetrics, TU Dresden Medizinische Fakultät Carl Gustav Carus, Dresden, Germany
- ²⁸Gynecologic Oncology Program, European Institute of Oncology, IRCCS, Milan and University of Milan-Bicocca, Milan, Italy
- ²⁹Clinical Research Unit, Institut Bergonie, Bordeaux, France
- ³⁰Department of Radiation Oncology, Leiden University Medical Center, Leiden, Netherlands

Presented at

These guidelines statements were developed by ESGO, ESTRO and ESP and are published in the *International Journal of Gynaecological Cancer, Radiotherapy & Oncology* and the *Virchows Archiv*.

Acknowledgements The authors thank ESGO, ESTRO, and ESP for their support. ESGO office, especially Kamila Macku, provided invaluable logistical and administrative support throughout the process. The authors also thank the 191 international reviewers (physicians and patient representatives, Appendix 2) for their valuable comments and suggestions. The European Society for Medical Oncology, Professor Cristiana Sessa and the ESMO-ESGO-ESTRO consensus conference working group are gratefully acknowledged for the previous 2014 Endometrial Consensus Conference. The authors wish to express sincere gratitude to Annette Hasenburg and Joachim Weis for describing the psycho-oncological aspects in this article.

Contributors The development group (including all authors) is collectively responsible for the decision to submit for publication. NCon (chair), CLC (co-chair), XM-G (co-chair) and FP (methodologist) have written the first draft of the manuscript. All other contributors have actively given personal input, reviewed the manuscript, and have given final approval before submission.

Funding All costs relating to the development process were covered from ESGO, ESTRO, and ESP funds.

Competing interests NCon: advisory boards for Seattle Genetics, AstraZeneca and Mersana, education fees from Medscape Oncology, and grants for travelling from Roche, Genmab and Amgen. IV: advisory boards for Amgen, AstraZeneca, Clovis Oncology, Carrick Therapeutics, Debiopharm International, F Hoffmann-La Roche, Genmab, GSK, Immunogen, Millenium Pharmaceuticals, MSD Belgium, Octimet Oncology, Oncoinvent, Pharmamar-Doctaforum Servicios, Roche, Sotio, Tesaro, Deciphera Pharmaceuticals and Verastem Oncology (fees for consulting to his university), contracted research (KU Leuven) for Oncoinvent AS and Genmab, corporate sponsored research for Amgen and Roche, and grants for travelling from Amgen, MSD/Merck, Roche, AstraZeneca and Tesaro. DC: advisory boards for AstraZeneca, Roche, Sotio and Novocure. MRM: personal financial interests for AstraZeneca, Biocard, Clovis Oncology, Geneos, Genmab, Karyopharm Therapeutics, Merck, Mersana, MSD, Oncology Venture, Pfizer, Roche, SeattleGenetics, SeraPrognostics, Sotio, Tesaro-GSK, ZaiLab; leadership role for Karyopharm Therapeutics, Sera Prognostics; institutional financial interests (study grants) for AstraZeneca, Boehringer Ingelheim, Clovis Oncology, Pfizer, Tesaro-GSK, Ultimovacs. JL: advisory boards for AstraZeneca, Pfizer, GSK, Eisai, MSD/Merck, Artios Pharma, Regeneron, Amgen and Clovis Oncology, and grants for travelling from Clovis Oncology. CC: advisory boards for MSD, Takeda and GSK, conducting research for TherAguiX and Roche, and grants for travelling from Takeda. AF: advisory boards for GSK and Johnson & Johnson SpA, and grants for travelling from Pharmmar and MSD Italia. CF: advisory boards for AstraZeneca, Clovis, Ethicon, Roche, MSD, GSK and Tesaro, and grants for travelling from Sequana. AGM: speakers' bureau activities for AstraZeneca, Pharmamar, Roche and GSK, advisory boards for Amgen, AstraZeneca, Clovis Oncology, Genmab, GSK, Immunogen, Merck Sharp & Dohme, Novartis, Oncoinvent, Pfizer/Merck, Pharmamar, Roche and Sotio, and grants for travelling from AstraZeneca, Pharmamar Roche and Tesaro. DL: advisory boards for Roche, Amgen, MSD, GSK, Clovis, AstraZeneca, Immunogen, Genmab, Pharmamar and Merck, and grants for travelling from Pharmamar, GSK, Roche and AstraZeneca. CM: consulting/advisory boards for Roche, Novartis, Amgen, MSD, AstraZeneca, Pfizer, Pharmamar, Cerulean, Vertex and Tesaro, funded research from EU, FWF, AstraZeneca and Roche, and honoraria/expenses from Roche, Novartis, Amgen, MSD, Pharmamar, AstraZeneca and Tesaro. JS: advisory boards for Roche, Eisai, MSD, AstraZeneca, Clovis, GSK and Tesaro. AT: advisory boards for Genmab; PW: advisory boards for Amgen, AstraZeneca, MSD, Novartis, Pfizer, Pharmamar, Lilly, Roche Pharma GmbH, TEVA, Eisai, Clovis and Tesaro, and grants for travelling from Roche Pharma GmbH, AstraZeneca, MSD, Amgen and Pfizer. NC: consulting and advisory services, speaking or writing engagements, public presentations for Roche, AstraZeneca, MSD, Pharmamar, Tesaro, GSK, Clovis, Advaxis, Pfizer, Takeda, Immunogen, Biocad, Amgen, Novartis and Ellipses, institutional financial interests for Roche, Pharmamar and AstraZeneca, and non-financial interests for ESMO clinical Guidelines (subject editor for gynecological cancer). XMG, SM, TB, SL, PM, RN, DOD, DQ, MRR, AS, AW, FP, and CLC: no conflicts of interest.

Patient consent for publication Not required.

Provenance and peer review Commissioned; internally peer reviewed.

Data availability statement All data relevant to the study are included in the article or uploaded as supplementary information.

ORCID iDs

Nicole Concin <http://orcid.org/0000-0002-9795-2643>
Jonathan Ledermann <http://orcid.org/0000-0003-3799-3539>
Christina Fotopoulou <http://orcid.org/0000-0001-6375-9645>
Denis Querleu <http://orcid.org/0000-0002-3984-4812>

REFERENCES

- 1 World Health Organization. GLOBOCAN 2018: estimated cancer incidence, mortality and prevalence worldwide in 2018, 2018. Available: <http://gco.iarc.fr/today/data/factsheets/cancers/24-Corpus-uteri-fact-sheet.pdf> [Accessed 29 Jul 2020].
- 2 Sant M, Chirlaque Lopez MD, Agresti R, et al. Survival of women with cancers of breast and genital organs in Europe

- 1999–2007: results of the EUROCARE-5 study. *Eur J Cancer* 2015;51:2191–205.
- 3 Colombo N, Creutzberg C, Amant F, et al. ESMO-ESGO-ESTRO consensus conference on endometrial cancer: diagnosis, treatment and follow-up. *Int J Gynecol Cancer* 2016;26:2–30.
 - 4 Colombo N, Creutzberg C, Amant F, et al. ESMO-ESGO-ESTRO consensus conference on endometrial cancer: diagnosis, treatment and follow-up. *Radiother Oncol* 2015;117:559–81.
 - 5 Colombo N, Creutzberg C, Amant F, et al. ESMO-ESGO-ESTRO consensus conference on endometrial cancer: diagnosis, treatment and follow-up. *Ann Oncol* 2016;27:16–41.
 - 6 Colombo N, Preti E, Landoni F, et al. Endometrial cancer: ESMO clinical practice guidelines for diagnosis, treatment and follow-up. *Ann Oncol* 2013;24 Suppl 6:vi33–8.
 - 7 Dykewicz CA. Summary of the guidelines for preventing opportunistic infections among hematopoietic stem cell transplant recipients. *Clin Infect Dis* 2001;33:139–44.
 - 8 Ryan NAJ, Glaire MA, Blake D, et al. The proportion of endometrial cancers associated with Lynch syndrome: a systematic review of the literature and meta-analysis. *Genet Med* 2019;21:2167–80.
 - 9 Cho KR, Cooper K, Croce S, et al. International Society of Gynecological Pathologists (ISGyP) endometrial cancer project: guidelines from the special techniques and ancillary studies group. *Int J Gynecol Pathol* 2019;38 Suppl 1:S114–22.
 - 10 Crosbie EJ, Ryan NAJ, Arends MJ, et al. The Manchester International Consensus Group recommendations for the management of gynecological cancers in Lynch syndrome. *Genet Med* 2019;21:2390–400.
 - 11 Mills AM, Liou S, Ford JM, et al. Lynch syndrome screening should be considered for all patients with newly diagnosed endometrial cancer. *Am J Surg Pathol* 2014;38:1501–9.
 - 12 Mojtahed A, Schrijver I, Ford JM, et al. A two-antibody mismatch repair protein immunohistochemistry screening approach for colorectal carcinomas, skin sebaceous tumors, and gynecologic tract carcinomas. *Mod Pathol* 2011;24:1004–14.
 - 13 Shia J, Tang LH, Vakiani E, et al. Immunohistochemistry as first-line screening for detecting colorectal cancer patients at risk for hereditary nonpolyposis colorectal cancer syndrome: a 2-antibody panel may be as predictive as a 4-antibody panel. *Am J Surg Pathol* 2009;33:1639–45.
 - 14 Møller P, Seppälä T, Bernstein I, et al. Cancer incidence and survival in Lynch syndrome patients receiving colonoscopic and gynaecological surveillance: first report from the prospective Lynch syndrome database. *Gut* 2017;66:464–72.
 - 15 Ryan NAJ, Morris J, Green K, et al. Association of mismatch repair mutation with age at cancer onset in Lynch syndrome: implications for stratified surveillance strategies. *JAMA Oncol* 2017;3:1702–6.
 - 16 Lachiewicz MP, Kravochuck SE, O'Malley MM, et al. Prevalence of occult gynecologic malignancy at the time of risk reducing and nonprophylactic surgery in patients with Lynch syndrome. *Gynecol Oncol* 2014;132:434–7.
 - 17 Kandoth C, Schultz N, et al. Cancer Genome Atlas Research Network. Integrated genomic characterization of endometrial carcinoma. *Nature* 2013;497:67–73.
 - 18 Piulats JM, Guerra E, Gil-Martín M, et al. Molecular approaches for classifying endometrial carcinoma. *Gynecol Oncol* 2017;145:200–7.
 - 19 Talhouk A, McConechy MK, Leung S, et al. A clinically applicable molecular-based classification for endometrial cancers. *Br J Cancer* 2015;113:299–310.
 - 20 Talhouk A, McConechy MK, Leung S, et al. Confirmation of ProMisE: a simple, genomics-based clinical classifier for endometrial cancer. *Cancer* 2017;123:802–13.
 - 21 Stelloo E, Nout RA, Osse EM, et al. Improved risk assessment by integrating molecular and clinicopathological factors in early-stage endometrial cancer—combined analysis of the PORTEC cohorts. *Clin Cancer Res* 2016;22:4215–24.
 - 22 León-Castillo A, de Boer SM, Powell ME, et al. Molecular classification of the PORTEC-3 trial for high-risk endometrial cancer: impact on prognosis and benefit from adjuvant therapy. *J Clin Oncol* 2020;38:3388–97.
 - 23 León-Castillo A, Gilvazquez E, Nout R, et al. Clinicopathological and molecular characterisation of 'multiple-classifier' endometrial carcinomas. *J Pathol* 2020;250:312–22.
 - 24 Vermij L, Smit V, Nout R, et al. Incorporation of molecular characteristics into endometrial cancer management. *Histopathology* 2020;76:52–63.
 - 25 Church DN, Stelloo E, Nout RA, et al. Prognostic significance of POLE proofreading mutations in endometrial cancer. *J Natl Cancer Inst* 2015;107.
 - 26 León-Castillo A, Britton H, McConechy MK, et al. Interpretation of somatic POLE mutations in endometrial carcinoma. *J Pathol* 2020;250:323–35.
 - 27 McAlpine J, Leon-Castillo A, Bosse T. The rise of a novel classification system for endometrial carcinoma; integration of molecular subclasses. *J Pathol* 2018;244:538–49.
 - 28 Köbel M, Nelson GS. Letter in response to: McAlpine J, Leon-Castillo a, Bosse T. the rise of a novel classification system for endometrial carcinoma; integration of molecular subclasses. *J Pathol* 2018; 244: 538-549. *J Pathol* 2018;245:249–50.
 - 29 Kommoss FKF, Karnezis AN, Kommoss F, et al. L1Cam further stratifies endometrial carcinoma patients with no specific molecular risk profile. *Br J Cancer* 2018;119:480–6.
 - 30 van der Putten LJM, Visser NCM, van de Vijver K, et al. L1CAM expression in endometrial carcinomas: an ENITEC collaboration study. *Br J Cancer* 2016;115:716–24.
 - 31 Van Gool IC, Stelloo E, Nout RA, et al. Prognostic significance of L1CAM expression and its association with mutant p53 expression in high-risk endometrial cancer. *Mod Pathol* 2016;29:174–81.
 - 32 Bosse T, Nout RA, Stelloo E, et al. L1 cell adhesion molecule is a strong predictor for distant recurrence and overall survival in early stage endometrial cancer: pooled PORTEC trial results. *Eur J Cancer* 2014;50:2602–10.
 - 33 WHO Classification of Tumours. *Female genital organ tumours, International agency for research on cancer IARC*. 5th edn. Lyon, 2020.
 - 34 Ali A, Black D, Soslow RA. Difficulties in assessing the depth of myometrial invasion in endometrial carcinoma. *Int J Gynecol Pathol* 2007;26:115–23.
 - 35 Luomaranta A, Leminen A, Loukovaara M. Magnetic resonance imaging in the assessment of high-risk features of endometrial carcinoma: a meta-analysis. *Int J Gynecol Cancer* 2015;25:837–42.
 - 36 Andreano A, Rechichi G, Rebora P, et al. MR diffusion imaging for preoperative staging of myometrial invasion in patients with endometrial cancer: a systematic review and meta-analysis. *Eur Radiol* 2014;24:1327–38.
 - 37 Das SK, Niu XK, Wang JL, et al. Usefulness of DWI in preoperative assessment of deep myometrial invasion in patients with endometrial carcinoma: a systematic review and meta-analysis. *Cancer Imaging* 2014;14.
 - 38 Deng L, Wang Q-P, Chen X, et al. The combination of diffusion- and T2-weighted imaging in predicting deep myometrial invasion of endometrial cancer. *J Comput Assist Tomogr* 2015;39:661–73.
 - 39 Alcázar JL, Gastón B, Navarro B, et al. Transvaginal ultrasound versus magnetic resonance imaging for preoperative assessment of myometrial infiltration in patients with endometrial cancer: a systematic review and meta-analysis. *J Gynecol Oncol* 2017;28:e86.
 - 40 Tanaka T, Terai Y, Fujiwara S, et al. Preoperative diffusion-weighted magnetic resonance imaging and intraoperative frozen sections for predicting the tumor grade in endometrioid endometrial cancer. *Oncotarget* 2018;9:36575–84.
 - 41 Sánchez MF, Causa Andrieu PI, Latapie C, et al. Diagnostic yield of magnetic resonance imaging and intraoperative frozen section in the determination of deep myometrial invasion in endometrial cancer. *Radiología* 2019;61:315–23.
 - 42 Fasmer KE, Bjørnerud A, Ytre-Hauge S, et al. Preoperative quantitative dynamic contrast-enhanced MRI and diffusion-weighted imaging predict aggressive disease in endometrial cancer. *Acta Radiol* 2018;59:1010–7.
 - 43 Taufiq M, Masroor I, Hussain Z. Diagnostic accuracy of diffusion weighted magnetic resonance imaging in the detection of myometrial invasion in endometrial carcinoma. *J Coll Physicians Surg Pak* 2016;26:13–17.
 - 44 Christensen JW, Dueholm M, Hansen ES, et al. Assessment of myometrial invasion in endometrial cancer using three-dimensional ultrasound and magnetic resonance imaging. *Acta Obstet Gynecol Scand* 2016;95:55–64.
 - 45 Arnaiz J, Muñoz A-B, Verna V, et al. Magnetic resonance imaging for the pre-surgical assessment of endometrial cancer: results in a routine clinical setting, outside dedicated trials; a cross-sectional study. *Anticancer Res* 2016;36:1891–4.
 - 46 Shrivastava S, Barmon D, Katakai AC, et al. Magnetic resonance imaging in pre-operative staging of endometrial cancer. *Indian J Cancer* 2016;53:181–5.
 - 47 Body N, Lavoué V, De Kerdaniel O, et al. Are preoperative histology and MRI useful for classification of endometrial cancer risk? *BMC Cancer* 2016;16:498.
 - 48 Rodríguez-Trujillo A, Martínez-Serrano MJ, Martínez-Román S, et al. Preoperative assessment of myometrial invasion in endometrial cancer by 3D ultrasound and diffusion-weighted magnetic

- resonance imaging: a comparative study. *Int J Gynecol Cancer* 2016;26:1105–10.
- 49 Horváth K, Pete I, Vereczkey I, *et al.* Evaluation of the accuracy of preoperative MRI in measuring myometrial infiltration in endometrial carcinoma. *Pathol Oncol Res* 2014;20:327–33.
- 50 Nougaret S, Reinhold C, Alsharif SS, *et al.* Endometrial cancer: combined MR volumetry and diffusion-weighted imaging for assessment of myometrial and lymphovascular invasion and tumor grade. *Radiology* 2015;276:797–808.
- 51 Ippolito D, Cadonici A, Bonaffini PA, *et al.* Semiquantitative perfusion combined with diffusion-weighted MR imaging in pre-operative evaluation of endometrial carcinoma: results in a group of 57 patients. *Magn Reson Imaging* 2014;32:464–72.
- 52 Tanaka T, Terai Y, Ono YJ, *et al.* Preoperative MRI and intraoperative frozen section diagnosis of myometrial invasion in patients with endometrial cancer. *Int J Gynecol Cancer* 2015;25:879–83.
- 53 Bonatti M, Stuefer J, Oberhofer N, *et al.* MRI for local staging of endometrial carcinoma: is endovenous contrast medium administration still needed? *Eur J Radiol* 2015;84:208–14.
- 54 Karataşlı V, Çakır İ, Şahin H, *et al.* Can preoperative magnetic resonance imaging replace intraoperative frozen sectioning in the evaluation of myometrial invasion for early-stage endometrial carcinoma? *Ginekoloj Pol* 2019;90:128–33.
- 55 Fujii S, Kido A, Baba T, *et al.* Subendometrial enhancement and peritumoral enhancement for assessing endometrial cancer on dynamic contrast enhanced MR imaging. *Eur J Radiol* 2015;84:581–9.
- 56 Yang T, Tian S, Li Y, *et al.* Magnetic resonance imaging (MRI) and three-dimensional transvaginal ultrasonography scanning for preoperative assessment of high risk in women with endometrial cancer. *Med Sci Monit* 2019;25:2024–31.
- 57 Ahmed M, Al-Khafaji JF, Class CA, *et al.* Can MRI help assess aggressiveness of endometrial cancer? *Clin Radiol* 2018;73:833.e11–833.e18.
- 58 Sahin H, Sarioglu FC, Bagci M, *et al.* Preoperative magnetic resonance volumetry in predicting myometrial invasion, lymphovascular space invasion, and tumor grade: is it valuable in International Federation of Gynecology and Obstetrics stage I endometrial cancer? *Int J Gynecol Cancer* 2018;28:666–74.
- 59 Yan B, Zhao T, Liang X, *et al.* Can the apparent diffusion coefficient differentiate the grade of endometrioid adenocarcinoma and the histological subtype of endometrial cancer? *Acta Radiol* 2018;59:363–70.
- 60 Zhang L, Liu A, Zhang T, *et al.* Use of diffusion tensor imaging in assessing superficial myometrial invasion by endometrial carcinoma: a preliminary study. *Acta Radiol* 2015;56:1273–80.
- 61 Bonatti M, Pedrinolla B, Cybulski AJ, *et al.* Prediction of histological grade of endometrial cancer by means of MRI. *Eur J Radiol* 2018;103:44–50.
- 62 Tsikouras P, Koukoulis Z, Bothou A, *et al.* Preoperative assessment in endometrial cancer: is triage for lymphadenectomy possible? *J Buon* 2017;22:34–43.
- 63 Zamani N, Modares Gilani M, Zamani F, *et al.* Utility of pelvic MRI and tumor markers HE4 and CA125 to predict depth of myometrial invasion and cervical involvement in endometrial cancer. *J Family Reprod Health* 2015;9:177–83.
- 64 Bourgioti C, Chatoupis K, Tzavara C, *et al.* Predictive ability of maximal tumor diameter on MRI for high-risk endometrial cancer. *Abdom Radiol* 2016;41:2484–95.
- 65 Ytre-Hauge S, Dybvik JA, Lundervold A, *et al.* Preoperative tumor texture analysis on MRI predicts high-risk disease and reduced survival in endometrial cancer. *J Magn Reson Imaging* 2018;48:1637–47.
- 66 Thieme SF, Colletini F, Sehouli J, *et al.* Preoperative evaluation of myometrial invasion in endometrial carcinoma: prospective intra-individual comparison of magnetic resonance volumetry, diffusion-weighted and dynamic contrast-enhanced magnetic resonance imaging. *Anticancer Res* 2018;38:4813–7.
- 67 Deng L, Wang Q-P, Yan R, *et al.* Combined subjective and quantitative analysis of magnetic resonance images could improve the diagnostic performance of deep myometrial invasion in endometrial cancer. *Clin Imaging* 2017;43:69–73.
- 68 Gallego JC, Porta A, Pardo MC, *et al.* Evaluation of myometrial invasion in endometrial cancer: comparison of diffusion-weighted magnetic resonance and intraoperative frozen sections. *Abdom Imaging* 2014;39:1021–6.
- 69 Brocker KA, Radtke JP, Hallscheidt P, *et al.* Comparison of the determination of the local tumor extent of primary endometrial cancer using clinical examination and 3 tesla magnetic resonance imaging compared to histopathology. *Arch Gynecol Obstet* 2019;299:1391–8.
- 70 Goel G, Rajanbabu A, Sandhya CJ, *et al.* A prospective observational study evaluating the accuracy of MRI in predicting the extent of disease in endometrial cancer. *Indian J Surg Oncol* 2019;10:220–4.
- 71 Cignini P, Vitale SG, Laganà AS, *et al.* Preoperative work-up for definition of lymph node risk involvement in early stage endometrial cancer: 5-year follow-up. *Updates Surg* 2017;69:75–82.
- 72 Soneji ND, Bharwani N, Ferri A, *et al.* Pre-operative MRI staging of endometrial cancer in a multicentre cancer network: can we match single centre study results? *Eur Radiol* 2018;28:4725–34.
- 73 Green RW, Valentin L, Alcazar JL, *et al.* Endometrial cancer off-line staging using two-dimensional transvaginal ultrasound and three-dimensional volume contrast imaging: intermethod agreement, interrater reliability and diagnostic accuracy. *Gynecol Oncol* 2018;150:438–45.
- 74 Takeuchi M, Matsuzaki K, Harada M. Evaluating myometrial invasion in endometrial cancer: comparison of reduced field-of-view diffusion-weighted imaging and dynamic contrast-enhanced MR imaging. *MRMS* 2018;17:28–34.
- 75 Ota T, Hori M, Onishi H, *et al.* Preoperative staging of endometrial cancer using reduced field-of-view diffusion-weighted imaging: a preliminary study. *Eur Radiol* 2017;27:5225–35.
- 76 Koplay M, Dogan NU, Erdogan H, *et al.* Diagnostic efficacy of diffusion-weighted MRI for pre-operative assessment of myometrial and cervical invasion and pelvic lymph node metastasis in endometrial carcinoma. *J Med Imaging Radiat Oncol* 2014;58:538–46.
- 77 Woo S, Kim SY, Cho JY, *et al.* Assessment of deep myometrial invasion of endometrial cancer on MRI: added value of second-opinion interpretations by radiologists subspecialized in gynaecologic oncology. *Eur Radiol* 2017;27:1877–82.
- 78 Alves I, Cunha TM. Clinical importance of second-opinion interpretations by radiologists specializing in gynecologic oncology at a tertiary cancer center: magnetic resonance imaging for endometrial cancer staging. *Radiol Bras* 2018;51:26–31.
- 79 Masroor I, Rashid S, Afzal S, *et al.* Diagnostic accuracy of pelvic MRI for determination of the cervical involvement in endometrial cancer. *J Coll Physicians Surg Pak* 2018;27:262–5.
- 80 Teng F, Zhang Y-F, Wang Y-M, *et al.* Contrast-enhanced MRI in preoperative assessment of myometrial and cervical invasion, and lymph node metastasis: diagnostic value and error analysis in endometrial carcinoma. *Acta Obstet Gynecol Scand* 2015;94:266–73.
- 81 Bhosale P, Ma J, Iyer R, *et al.* Feasibility of a reduced field-of-view diffusion-weighted (rFOV) sequence in assessment of myometrial invasion in patients with clinical FIGO stage I endometrial cancer. *J Magn Reson Imaging* 2016;43:316–24.
- 82 Lin G, Huang Y-T, Chao A, *et al.* Endometrial cancer with cervical stromal invasion: diagnostic accuracy of diffusion-weighted and dynamic contrast enhanced MR imaging at 3T. *Eur Radiol* 2017;27:1867–76.
- 83 Alcazar JL, Pineda L, Martinez-Astorquiza Corral T, *et al.* Transvaginal/transrectal ultrasound for assessing myometrial invasion in endometrial cancer: a comparison of six different approaches. *J Gynecol Oncol* 2015;26:201–7.
- 84 Eriksson LSE, Lindqvist PG, Flöter Rådestad A, *et al.* Transvaginal ultrasound assessment of myometrial and cervical stromal invasion in women with endometrial cancer: interobserver reproducibility among ultrasound experts and gynecologists. *Ultrasound Obstet Gynecol* 2015;45:476–82.
- 85 Vieillefosse S, Huchon C, Chammings F, *et al.* Assessment of different pre and intra-operative strategies to predict the actual ESMO risk group and to establish the appropriate indication of lymphadenectomy in endometrial cancer. *J Gynecol Obstet Hum Reprod* 2018;47:517–23.
- 86 Jantarsaengaram S, Praditphol N, Tansathit T, *et al.* Three-dimensional ultrasound with volume contrast imaging for preoperative assessment of myometrial invasion and cervical involvement in women with endometrial cancer. *Ultrasound Obstet Gynecol* 2014;43:569–74.
- 87 Pineda L, Alcázar JL, Caparrós M, *et al.* Agreement between preoperative transvaginal ultrasound and intraoperative macroscopic examination for assessing myometrial infiltration in low-risk endometrioid carcinoma. *Ultrasound Obstet Gynecol* 2016;47:369–73.
- 88 Frühauf F, Zikan M, Semerádova I, *et al.* The diagnostic accuracy of ultrasound in assessment of myometrial invasion in endometrial cancer: subjective assessment versus objective techniques. *Biomed Res Int* 2017;2017:1–10.
- 89 Bollineni VR, Ytre-Hauge S, Bollineni-Balabay O, *et al.* High diagnostic value of 18F-FDG PET/CT in endometrial cancer:

- systematic review and meta-analysis of the literature. *J Nucl Med* 2016;57:879–85.
- 90 Legros M, Marguerite F, Tardieu A, *et al.* Para-aortic lymph node invasion in high-risk endometrial cancer: performance of (18)FDG PET-CT. *Anticancer Res* 2019;39:619–25.
- 91 Kim HJ, Cho A, Yun M, *et al.* Comparison of FDG PET/CT and MRI in lymph node staging of endometrial cancer. *Ann Nucl Med* 2016;30:104–13.
- 92 Chung HH, Cheon GJ, Kim HS, *et al.* Preoperative PET/CT standardized FDG uptake values of pelvic lymph nodes as a significant prognostic factor in patients with endometrial cancer. *Eur J Nucl Med Mol Imaging* 2014;41:1793–9.
- 93 Atakul BK, Taşkın S, Soydal Ç, *et al.* Preoperative 18F-fluorodeoxyglucose positron emission tomography/CT in prediction of uterine risk factors and lymph node metastasis: an analysis of 111 endometrioid endometrial cancer patients. *Gynecol Obstet Invest* 2017;82:340–8.
- 94 Kulkarni R, Bhat RA, Dhakharia V, *et al.* Role of positron emission tomography/computed tomography in preoperative assessment of carcinoma endometrium—a retrospective analysis. *Indian J Surg Oncol* 2019;10:225–31.
- 95 Tanaka T, Terai Y, Yamamoto K, *et al.* The diagnostic accuracy of fluorodeoxyglucose-positron emission tomography/computed tomography and sentinel node biopsy in the prediction of pelvic lymph node metastasis in patients with endometrial cancer. *Medicine* 2018;97:e12522.
- 96 Bese T, Sal V, Demirkiran F, *et al.* The combination of preoperative fluorodeoxyglucose positron emission tomography/computed tomography and sentinel lymph node mapping in the surgical management of endometrioid endometrial cancer. *Int J Gynecol Cancer* 2016;26:1228–38.
- 97 Park J-Y, Lee JJ, Choi HJ, *et al.* The value of preoperative positron emission tomography/computed tomography in node-negative endometrial cancer on magnetic resonance imaging. *Ann Surg Oncol* 2017;24:2303–10.
- 98 Gülseren V, Kocaer M, Çelikkol Güngördük Ö, *et al.* Is the measurement of the size of uterine lesions with positron emission tomography consistent in pre- and postmenopausal periods in endometrioid-type endometrial cancer? *Turk J Obstet Gynecol* 2018;15:60–4.
- 99 Gholkar NS, Saha SC, Prasad G, *et al.* The accuracy of integrated [(18)F] fluorodeoxyglucose-positron emission tomography/computed tomography in detection of pelvic and para-aortic nodal metastasis in patients with high risk endometrial cancer. *World J Nucl Med* 2014;13:170–7.
- 100 Mayoral M, Paredes P, Domènech B, *et al.* ¹⁸F-FDG PET/CT and sentinel lymph node biopsy in the staging of patients with cervical and endometrial cancer. Role of dual-time-point imaging. *Rev Esp Med Nucl Imagen Mol* 2017;36:20–6.
- 101 Ghooshkhaneh H, Treglia G, Sabouri G, *et al.* Risk stratification and prognosis determination using 18F-FDG PET imaging in endometrial cancer patients: a systematic review and meta-analysis. *Gynecol Oncol* 2014;132:669–76.
- 102 Dai S, Nahas S, Murphy JK, *et al.* Impact and cost of preoperative computed tomography imaging on the management of patients diagnosed with high-grade endometrial cancer. *Int J Gynecol Obstet* 2019;145:219–24.
- 103 Bogani G, Gostout BS, Dowdy SC, *et al.* Clinical utility of preoperative computed tomography in patients with endometrial cancer. *Int J Gynecol Cancer* 2017;27:1685–93.
- 104 Janda M, GebSKI V, Davies LC, *et al.* Effect of total laparoscopic hysterectomy vs total abdominal hysterectomy on disease-free survival among women with stage I endometrial cancer. *JAMA* 2017;317:1224–33.
- 105 Walker JL, Piedmonte MR, Spirtos NM, *et al.* Recurrence and survival after random assignment to laparoscopy versus laparotomy for comprehensive surgical staging of uterine cancer: Gynecologic Oncology Group LAP2 study. *JCO* 2012;30:695–700.
- 106 Togami S, Kawamura T, Fukuda M, *et al.* Learning curve and surgical outcomes for laparoscopic surgery, including pelvic lymphadenectomy, for early stage endometrial cancer. *Jpn J Clin Oncol* 2019;49:521–4.
- 107 Deura I, Shimada M, Azuma Y, *et al.* Comparison of laparoscopic surgery and conventional laparotomy for surgical staging of patients with presumed low-risk endometrial cancer: the current state of Japan. *Taiwan J Obstet Gynecol* 2019;58:99–104.
- 108 Ghazali WHW, Jamil S, Sharin I. Laparoscopic versus laparotomy: Staging surgery for endometrial cancer – Malaysia's early experience. *Gynecol Minim Invasive Ther* 2019;8:25–9.
- 109 Vardar MA, Gulec UK, Guzel AB, *et al.* Laparoscopic surgery for low, intermediate and high-risk endometrial cancer. *J Gynecol Oncol* 2019;30:e24.
- 110 Pookunju AP, Ayyappan S. Technique of laparoscopic hysterectomy and pelvic lymphadenectomy for endometrial cancer. *Indian J Surg Oncol* 2018;9:290–3.
- 111 Wollinga T, Ezendam NPM, Eggink FA, *et al.* Implementation of laparoscopic hysterectomy for endometrial cancer over the past decade. *Gynecol Surg* 2018;15:7.
- 112 Van den Bosch A, Mertens H. Implementation of laparoscopic surgery for endometrial cancer: work in progress. *Facts Views Vis Obgyn* 2016;8:23–30.
- 113 Chu L-H, Chang W-C, Sheu B-C. Comparison of the laparoscopic versus conventional open method for surgical staging of endometrial carcinoma. *Taiwan J Obstet Gynecol* 2016;55:188–92.
- 114 Favero G, Anton C, Le X, *et al.* Oncologic safety of laparoscopy in the surgical treatment of type II endometrial cancer. *Int J Gynecol Cancer* 2016;26:1673–8.
- 115 Bennich G, Rudnicki M, Lassen PD. Laparoscopic surgery for early endometrial cancer. *Acta Obstet Gynecol Scand* 2016;95:894–900.
- 116 Lee C-L, Kusunoki S, Huang K-G, *et al.* Long-term survival outcomes of laparoscopic staging surgery in treating endometrial cancer: 20 years of follow-up. *Taiwan J Obstet Gynecol* 2016;55:545–51.
- 117 Berretta R, Gizzo S, Noventa M, *et al.* Quality of life in patients affected by endometrial cancer: comparison among laparotomy, laparoscopy and vaginal approach. *Pathol Oncol Res* 2015;21:811–6.
- 118 Yin X, Shi M, Xu J, *et al.* Perioperative and long-term outcomes of laparoscopy and laparotomy for endometrial carcinoma. *Int J Clin Exp Med* 2015;8:19093–9.
- 119 Kroft J, Li Q, Saskin R, *et al.* Trends over time in the use of laparoscopic hysterectomy for the treatment of endometrial cancer. *Gynecol Oncol* 2015;138:536–41.
- 120 Pawlowski PS, Ajdacka U. The role of laparoscopy in the surgical treatment of endometrial cancer. *Wiitm* 2015;1:44–8.
- 121 Gao H, Zhang Z. Laparoscopy versus laparotomy in the treatment of high-risk endometrial cancer: a propensity score matching analysis. *Medicine* 2015;94:e1245.
- 122 Şenol T, Polat M, Şanverdi I, *et al.* Laparoscopic staging of endometrial cancer: does it have any impact on survival? *Turk J Obstet Gynecol* 2015;12:139–43.
- 123 Palomba S, Ghezzi F, Falbo A, *et al.* Conversion in endometrial cancer patients scheduled for laparoscopic staging: a large multicenter analysis: conversions and endometrial cancer. *Surg Endosc* 2014;28:3200–9.
- 124 Lee C-L, Huang K-G, Wu P-J, *et al.* Long-term survival outcome of laparoscopic staging surgery for endometrial cancer in Taiwanese experience. *Taiwan J Obstet Gynecol* 2014;53:57–61.
- 125 Terai Y, Tanaka T, Sasaki H, *et al.* Total laparoscopic modified radical hysterectomy with lymphadenectomy for endometrial cancer compared with laparotomy. *J Obstet Gynaecol Res* 2014;40:570–5.
- 126 Koskas M, Jozwiak M, Fournier M, *et al.* Long-term oncological safety of minimally invasive surgery in high-risk endometrial cancer. *Eur J Cancer* 2016;65:185–91.
- 127 Uccella S, Bonzini M, Palomba S, *et al.* Laparoscopic vs. open treatment of endometrial cancer in the elderly and very elderly: an age-stratified multicenter study on 1606 women. *Gynecol Oncol* 2016;141:211–7.
- 128 Bogani G, Cromi A, Uccella S, *et al.* Perioperative and long-term outcomes of laparoscopic, open abdominal, and vaginal surgery for endometrial cancer in patients aged 80 years or older. *Int J Gynecol Cancer* 2014;24:894–900.
- 129 Baek M-H, Lee S-W, Park J-Y, *et al.* Feasibility and safety of laparoscopic surgery for obese Korean women with endometrial cancer: long-term results at a single institution. *J Korean Med Sci* 2014;29:1536–43.
- 130 Bogani G, Cromi A, Uccella S, *et al.* Laparoscopic staging in women older than 75 years with early-stage endometrial cancer: comparison with open surgical operation. *Menopause* 2014;21:945–51.
- 131 Freeman AH, Barrie A, Lyon L, *et al.* Venous thromboembolism following minimally invasive surgery among women with endometrial cancer. *Gynecol Oncol* 2016;142:267–72.
- 132 Raventós-Tato RM, de la Torre-Fernández de Vega J, Sánchez-Iglesias JL, *et al.* Surgical approaches in women with endometrial cancer with a body mass index greater than 35 kg/m². *J Obstet Gynaecol Res* 2019;45:195–202.
- 133 Bishop EA, Java JJ, Moore KN, *et al.* Surgical outcomes among elderly women with endometrial cancer treated by laparoscopic

- hysterectomy: a NRG/Gynecologic Oncology Group study. *Am J Obstet Gynecol* 2018;218:109.e1–109.e11.
- 134 Casarin J, Multinu F, Ubl DS, *et al.* Adoption of minimally invasive surgery and decrease in surgical morbidity for endometrial cancer treatment in the United States. *Obstet Gynecol* 2018;131:304–11.
- 135 Ee WW, Nellore V, McMullen W, *et al.* Laparoscopic hysterectomy for endometrial cancer: impact of age on clinical outcomes. *J Obstet Gynaecol* 2018;38:734.
- 136 Singh S, Swarer K, Resnick K. Longer operative time is associated with increased post-operative complications in patients undergoing minimally-invasive surgery for endometrial cancer. *Gynecol Oncol* 2017;147:554–7.
- 137 Bregar AJ, Melamed A, Diver E, *et al.* Minimally invasive staging surgery in women with early-stage endometrial cancer: analysis of the National Cancer Data Base. *Ann Surg Oncol* 2017;24:1677–87.
- 138 Monterossi G, Ghezzi F, Vizza E, *et al.* Minimally invasive approach in type II endometrial cancer: is it wise and safe? *J Minim Invasive Gynecol* 2017;24:438–45.
- 139 Barber EL, Gehrig PA, Clarke-Pearson DL. Venous thromboembolism in minimally invasive compared with open hysterectomy for endometrial cancer. *Obstet Gynecol* 2016;128:121–6.
- 140 Pulman KJ, Dason ES, Philp L, *et al.* Comparison of three surgical approaches for staging lymphadenectomy in high-risk endometrial cancer. *Int J Gynecol Obstet* 2017;136:315–9.
- 141 Marcos-Sanmartín J, López Fernández JA, Sánchez-Payá J, *et al.* Does the type of surgical approach and the use of uterine manipulators influence the disease-free survival and recurrence rates in early-stage endometrial cancer? *Int J Gynecol Cancer* 2016;26:1722–6.
- 142 Tanaka T, Terai Y, Hayashi S, *et al.* Comparison between laparoscopy and laparotomy in systematic para-aortic lymphadenectomy for patients with endometrial cancer: a retrospective multicenter study. *J Gynecol Surg* 2017;33:105–10.
- 143 Galaal K, Donkers H, Bryant A, *et al.* Laparoscopy versus laparotomy for the management of early stage endometrial cancer. *Cochrane Database Syst Rev* 2018;10.
- 144 Asher R, Obermair A, Janda M, *et al.* Disease-free and survival outcomes for total laparoscopic hysterectomy compared with total abdominal hysterectomy in early-stage endometrial carcinoma: a meta-analysis. *Int J Gynecol Cancer* 2018;28:529–38.
- 145 Mahajan V. Prospective nonrandomized comparative study of laparoscopic versus open surgical staging for endometrial cancer in India. *Indian J Surg Oncol* 2018;9:133–40.
- 146 Jørgensen SL, Mogensen O, Wu C, *et al.* Nationwide introduction of minimally invasive robotic surgery for early-stage endometrial cancer and its association with severe complications. *JAMA Surg* 2019;154:530.
- 147 Kyrgiou M, Swart AM, Qian W, *et al.* A comparison of outcomes following laparoscopic and open hysterectomy with or without lymphadenectomy for presumed early-stage endometrial cancer: results from the Medical Research Council ASTEC trial. *Int J Gynecol Cancer* 2015;25:1424–36.
- 148 Park DA, Lee DH, Kim SW, *et al.* Comparative safety and effectiveness of robot-assisted laparoscopic hysterectomy versus conventional laparoscopy and laparotomy for endometrial cancer: a systematic review and meta-analysis. *Eur J Surg Oncol* 2016;42:1303–14.
- 149 Ran L, Jin J, Xu Y, *et al.* Comparison of robotic surgery with laparoscopy and laparotomy for treatment of endometrial cancer: a meta-analysis. *PLoS One* 2014;9:e108361.
- 150 Nevis IF, Vali B, Higgins C, *et al.* Robot-assisted hysterectomy for endometrial and cervical cancers: a systematic review. *J Robot Surg* 2017;11:1–16.
- 151 Lundin ES, Wodlin NB, Nilsson L, *et al.* A prospective randomized assessment of quality of life between open and robotic hysterectomy in early endometrial cancer. *Int J Gynecol Cancer* 2019. doi:10.1136/ijgc-2019-000285. [Epub ahead of print: 28 Mar 2019].
- 152 Herling SF, Møller AM, Palle C, *et al.* Robotic-assisted laparoscopic hysterectomy for women with endometrial cancer. *Dan Med J* 2017;64.
- 153 Uccella S, Bonzini M, Palomba S, *et al.* Impact of obesity on surgical treatment for endometrial cancer: a multicenter study comparing laparoscopy vs open surgery, with propensity-matched analysis. *J Minim Invasive Gynecol* 2016;23:53–61.
- 154 Corrado G, Mereu L, Bogliolo S, *et al.* Robotic single site staging in endometrial cancer: a multi-institution study. *Eur J Surg Oncol* 2016;42:1506–11.
- 155 Backes FJ, El Naggar AC, Farrell MR, *et al.* Perioperative outcomes for laparotomy compared to robotic surgical staging of endometrial cancer in the elderly: a retrospective cohort. *Int J Gynecol Cancer* 2016;26:1717–21.
- 156 Guy MS, Sheeder J, Behbakht K, *et al.* Comparative outcomes in older and younger women undergoing laparotomy or robotic surgical staging for endometrial cancer. *Am J Obstet Gynecol* 2016;214:350.e1–350.e10.
- 157 Herling SF, Havemann MC, Palle C, *et al.* Robotic-Assisted laparoscopic hysterectomy seems safe in women with early-stage endometrial cancer. *Dan Med J* 2015;62:A5109.
- 158 Beck TL, Schiff MA, Goff BA, *et al.* Robotic, laparoscopic, or open hysterectomy: surgical outcomes by approach in endometrial cancer. *J Minim Invasive Gynecol* 2018;25:986–93.
- 159 Doo DW, Guntupalli SR, Corr BR, *et al.* Comparative surgical outcomes for endometrial cancer patients 65 years old or older staged with robotics or laparotomy. *Ann Surg Oncol* 2015;22:3687–94.
- 160 Park HK, Helenowski IB, Berry E, *et al.* A comparison of survival and recurrence outcomes in patients with endometrial cancer undergoing robotic versus open surgery. *J Minim Invasive Gynecol* 2015;22:961–7.
- 161 Feuer GA, Lakhi N, Woo A, *et al.* Robotic surgery for staging of serous papillary and clear cell carcinoma of the endometrium. *Int J Med Robotics Comput Assist Surg* 2014;10:306–13.
- 162 Pant A, Schink J, Lurain J. Robotic surgery compared with laparotomy for high-grade endometrial cancer. *J Robot Surg* 2014;8:163–7.
- 163 Safdieh J, Lee Y-C, Wong A, *et al.* A comparison of outcomes between open hysterectomy and robotic-assisted hysterectomy for endometrial cancer using the National Cancer Database. *Int J Gynecol Cancer* 2017;27:1508–16.
- 164 Wright JD, Burke WM, Tergas AI, *et al.* Comparative effectiveness of minimally invasive hysterectomy for endometrial cancer. *JCO* 2016;34:1087–96.
- 165 Barraez D, Godoy H, McElrath T, *et al.* Low incidence of port-site metastasis after robotic assisted surgery for endometrial cancer staging: descriptive analysis. *J Robot Surg* 2015;9:91–5.
- 166 Yoon A, Yoo H-N, Lee Y-Y, *et al.* Robotic single-port hysterectomy, adnexectomy, and lymphadenectomy in endometrial cancer. *J Minim Invasive Gynecol* 2015;22:322.
- 167 Geppert B, Persson J. Robotic infrarenal paraaortic and pelvic nodal staging for endometrial cancer: feasibility and lymphatic complications. *Acta Obstet Gynecol Scand* 2015;94:1074–81.
- 168 Damiani GR, Turilli D, Cormio G, *et al.* Robotic approach using simple and radical hysterectomy for endometrial cancer with long-term follow-up evaluation. *Int J Med Robotics Comput Assist Surg* 2016;12:109–13.
- 169 Bige O, Demir A, Saatli B, *et al.* Laparoscopy versus laparotomy for the management of endometrial carcinoma in morbidly obese patients: a prospective study. *J Turkish German Gynecol Assoc* 2015;16:164–9.
- 170 Salehi S, Åvall-Lundqvist E, Legerstam B, *et al.* Robot-assisted laparoscopy versus laparotomy for infrarenal paraaortic lymphadenectomy in women with high-risk endometrial cancer: a randomised controlled trial. *Eur J Cancer* 2017;79:81–9.
- 171 Salehi S, Brandberg Y, Åvall-Lundqvist E, *et al.* Long-term quality of life after comprehensive surgical staging of high-risk endometrial cancer – results from the RASHEC trial. *Acta Oncol* 2018;57:1671–6.
- 172 Signorelli M, Lissoni AA, Cormio G, *et al.* Modified radical hysterectomy versus extrafascial hysterectomy in the treatment of stage I endometrial cancer: results from the ILIADE randomized study. *Ann Surg Oncol* 2009;16:3431–41.
- 173 Kaban A, Topuz S, Erdem B, *et al.* Is omentectomy necessary for non-endometrioid endometrial cancer. *Gynecol Obstet Invest* 2018;83:482–6.
- 174 Joo WD, Schwartz PE, Rutherford TJ, *et al.* Microscopic omental metastasis in clinical stage I endometrial cancer: a meta-analysis. *Ann Surg Oncol* 2015;22:3695–700.
- 175 Ross MS, Elishaev E, Berger JL, *et al.* Prognostic significance of omental disease and the role of omental sampling in patients with uterine carcinosarcoma. *Int J Gynecol Cancer* 2018;28:254–9.
- 176 Lee B, Suh DH, Kim K, *et al.* Influence of positive peritoneal cytology on prognostic factors and survival in early-stage endometrial cancer: a systematic review and meta-analysis. *Jpn J Clin Oncol* 2016;46:711–7.
- 177 Matsuo K, Yabuno A, Hom MS, *et al.* Significance of abnormal peritoneal cytology on survival of women with stage I–II endometrioid endometrial cancer. *Gynecol Oncol* 2018;149:301–9.
- 178 Seagle B-LL, Alexander AL, Lantsman T, *et al.* Prognosis and treatment of positive peritoneal cytology in early endometrial

- cancer: matched cohort analyses from the National Cancer Database. *Am J Obstet Gynecol* 2018;218:329.e1–329.e15.
- 179 Bogani G, Murgia F, Ditto A, et al. Sentinel node mapping vs. lymphadenectomy in endometrial cancer: a systematic review and meta-analysis. *Gynecol Oncol* 2019;153:676–83.
- 180 Leitao MM. Sentinel lymph node mapping in patients with endometrial carcinoma: less can be more. *Curr Obstet Gynecol Rep* 2016;5:279–85.
- 181 Rossi EC, Kowalski LD, Scalici J, et al. A comparison of sentinel lymph node biopsy to lymphadenectomy for endometrial cancer staging (FIRES trial): a multicentre, prospective, cohort study. *Lancet Oncol* 2017;18:384–92.
- 182 Persson J, Salehi S, Bollino M, et al. Pelvic Sentinel lymph node detection in High-Risk Endometrial Cancer (SHREC-trial)—the final step towards a paradigm shift in surgical staging. *Eur J Cancer* 2019;116:77–85.
- 183 Darai E, Dubernard G, Bats A-S, et al. Sentinel node biopsy for the management of early stage endometrial cancer: long-term results of the SENTI-ENDO study. *Gynecol Oncol* 2015;136:54–9.
- 184 Renz M, Marjon N, Devereaux K, et al. Immediate intraoperative sentinel lymph node analysis by frozen section is predictive of lymph node metastasis in endometrial cancer. *J Robot Surg* 2020;14:35–40.
- 185 How JA, O'Farrell P, Amajoud Z, et al. Sentinel lymph node mapping in endometrial cancer: a systematic review and meta-analysis. *Minerva Ginecol* 2018;70:194–214.
- 186 Lin H, Ding Z, Kota VG, et al. Sentinel lymph node mapping in endometrial cancer: a systematic review and meta-analysis. *Oncotarget* 2017;8:46601–10.
- 187 Staley A, Sullivan SA, Rossi EC. Sentinel lymph node technique in endometrial cancer. *Obstet Gynecol Surv* 2017;72:289–95.
- 188 Tschernichovsky R, Diver EJ, Schorge JO, et al. The role of lymphadenectomy versus sentinel lymph node biopsy in early-stage endometrial cancer. *Am J Clin Oncol* 2016;39:516–21.
- 189 Bodurtha Smith AJ, Fader AN, Tanner EJ. Sentinel lymph node assessment in endometrial cancer: a systematic review and meta-analysis. *Am J Obstet Gynecol* 2017;216:459–76.
- 190 Wang L, Liu F. Meta-analysis of laparoscopy sentinel lymph node mapping in endometrial cancer. *Arch Gynecol Obstet* 2018;298:505–10.
- 191 Baiocchi G, Mantoan H, Kumagai LY, et al. The impact of sentinel node-mapping in staging high-risk endometrial cancer. *Ann Surg Oncol* 2017;24:3981–7.
- 192 Tanner E, Puechl A, Levinson K, et al. Use of a novel sentinel lymph node mapping algorithm reduces the need for pelvic lymphadenectomy in low-grade endometrial cancer. *Gynecol Oncol* 2017;147:535–40.
- 193 Martinelli F, Ditto A, Signorelli M, et al. Sentinel node mapping in endometrial cancer following hysteroscopic injection of tracers: a single center evaluation over 200 cases. *Gynecol Oncol* 2017;146:525–30.
- 194 Buda A, Di Martino G, Restaino S, et al. The impact on survival of two different staging strategies in apparent early stage endometrial cancer comparing sentinel lymph nodes mapping algorithm and selective lymphadenectomy: an Italian retrospective analysis of two reference centers. *Gynecol Oncol* 2017;147:528–34.
- 195 Yamagami W, Susumu N, Kataoka F, et al. A comparison of dye versus fluorescence methods for sentinel lymph node mapping in endometrial cancer. *Int J Gynecol Cancer* 2017;27:1517–24.
- 196 Touhami O, Grégoire J, Renaud M-C, et al. Performance of sentinel lymph node (SLN) mapping in high-risk endometrial cancer. *Gynecol Oncol* 2017;147:549–53.
- 197 Papadia A, Buda A, Gasparri ML, et al. The impact of different doses of indocyanine green on the sentinel lymph-node mapping in early stage endometrial cancer. *J Cancer Res Clin Oncol* 2018;144:2187–91.
- 198 Eoh KJ, Lee YJ, Kim H-S, et al. Two-step sentinel lymph node mapping strategy in endometrial cancer staging using fluorescent imaging: a novel sentinel lymph node tracer injection procedure. *Surg Oncol* 2018;27:514–9.
- 199 Ducie JA, Eriksson AGZ, Ali N, et al. Comparison of a sentinel lymph node mapping algorithm and comprehensive lymphadenectomy in the detection of stage IIIC endometrial carcinoma at higher risk for nodal disease. *Gynecol Oncol* 2017;147:541–8.
- 200 Tanner EJ, Ojalvo L, Stone RL, et al. The utility of sentinel lymph node mapping in high-grade endometrial cancer. *Int J Gynecol Cancer* 2017;27:1416–21.
- 201 How J, Gauthier C, Abitbol J, et al. Impact of sentinel lymph node mapping on recurrence patterns in endometrial cancer. *Gynecol Oncol* 2017;144:503–9.
- 202 Papadia A, Zapardiel I, Bussi B, et al. Sentinel lymph node mapping in patients with stage I endometrial carcinoma: a focus on bilateral mapping identification by comparing radiotracer Tc99m with blue dye versus indocyanine green fluorescent dye. *J Cancer Res Clin Oncol* 2017;143:475–80.
- 203 Tanaka T, Terai Y, Fujiwara S, et al. The detection of sentinel lymph nodes in laparoscopic surgery can eliminate systemic lymphadenectomy for patients with early stage endometrial cancer. *Int J Clin Oncol* 2018;23:305–13.
- 204 Buda A, Gasparri ML, Puppo A, et al. Lymph node evaluation in high-risk early stage endometrial cancer: a multi-institutional retrospective analysis comparing the sentinel lymph node (SLN) algorithm and SLN with selective lymphadenectomy. *Gynecol Oncol* 2018;150:261–6.
- 205 Buda A, Bussi B, Di Martino G, et al. Sentinel lymph node mapping with near-infrared fluorescent imaging using indocyanine green: a new tool for laparoscopic platform in patients with endometrial and cervical cancer. *J Minim Invasive Gynecol* 2016;23:265–9.
- 206 Buda A, Di Martino G, Vecchione F, et al. Optimizing strategies for sentinel lymph node mapping in early-stage cervical and endometrial cancer: comparison of real-time fluorescence with indocyanine green and methylene blue. *Int J Gynecol Cancer* 2015;25:1513–8.
- 207 Signorelli M, Crivellaro C, Buda A, et al. Staging of high-risk endometrial cancer with PET/CT and sentinel lymph node mapping. *Clin Nucl Med* 2015;40:780–5.
- 208 Rajanbabu A, Venkatesan R, Chandramouli S, et al. Sentinel node detection in endometrial cancer using indocyanine green and fluorescence imaging—a case report. *Ecancermedicalsecience* 2015;9:549.
- 209 Surynt E, Reinholz-Jaskolska M, Bidzinski M. Laparoscopic sentinel lymph node mapping after cervical injection of indocyanine green for endometrial cancer – preliminary report. *Wiitm* 2015;3:406–12.
- 210 Chen C-H, Chen H-H, Liu W-M. Detection of sentinel lymph node mapping using indocyanine green in the management of endometrial cancer: a pilot study. *J Minim Invasive Gynecol* 2015;22:S239.
- 211 Plante M, Touhami O, Trinh X-B, et al. Sentinel node mapping with indocyanine green and endoscopic near-infrared fluorescence imaging in endometrial cancer. A pilot study and review of the literature. *Gynecol Oncol* 2015;137:443–7.
- 212 Sinno AK, Fader AN, Roche KL, et al. A comparison of colorimetric versus fluorometric sentinel lymph node mapping during robotic surgery for endometrial cancer. *Gynecol Oncol* 2014;134:281–6.
- 213 Blakely M, Liu Y, Rahaman J, et al. Sentinel lymph node ultra-staging as a supplement for endometrial cancer intraoperative frozen section deficiencies. *Int J Gynecol Pathol* 2019;38:52–8.
- 214 Multinu F, Casarin J, Cappuccio S, et al. Ultrastaging of negative pelvic lymph nodes to decrease the true prevalence of isolated paraaortic dissemination in endometrial cancer. *Gynecol Oncol* 2019;154:60–4.
- 215 Gorostidi M, Villalain C, Ruiz R, et al. Maximizing sentinel lymph node detection: aortic sentinel lymph node detection in endometrial cancer. *J Minim Invasive Gynecol* 2019;26:23–4.
- 216 Taşkın S, Altın D, Şükür YE, et al. Extrapelvic sentinel lymph nodes in endometrial cancer patients with unmapped pelvic side: a brief report. *Int J Gynecol Cancer* 2018;28:700–3.
- 217 Fernandez-Prada S, Delgado-Sanchez E, De Santiago J, et al. Laparoscopic sentinel node biopsy using real-time 3-dimensional single-photon emission computed tomographic guidance in endometrial cancer. *J Minim Invasive Gynecol* 2015;22:1075–8.
- 218 Ruiz R, Gorostidi M, Jaunarena I, et al. Sentinel node biopsy in endometrial cancer with dual cervical and fundal indocyanine green injection. *Int J Gynecol Cancer* 2018;28:139–44.
- 219 Euscher E, Sui D, Soliman P, et al. Ultrastaging of sentinel lymph nodes in endometrial carcinoma according to use of 2 different methods. *Int J Gynecol Pathol* 2018;37:242–51.
- 220 Schlappe BA, Weaver AL, Ducie JA, et al. Multicenter study comparing oncologic outcomes between two nodal assessment methods in patients with deeply invasive endometrioid endometrial carcinoma: a sentinel lymph node algorithm versus a comprehensive pelvic and paraaortic lymphadenectomy. *Gynecol Oncol* 2018;151:235–42.
- 221 Buda A, Restaino S, Di Martino G, et al. The impact of the type of nodal assessment on prognosis in patients with high-intermediate and high-risk ESMO/ESGO/ESTRO group endometrial cancer. A multicenter Italian study. *Eur J Surg Oncol* 2018;44:1562–7.
- 222 Mendivil AA, Abaid LN, Brown JV, et al. The safety and feasibility of minimally invasive sentinel lymph node staging using indocyanine green in the management of endometrial cancer. *Eur J Obstet Gynecol Reprod Biol* 2018;224:29–32.

- 223 Restaino S, Ronsini C, Finelli A, *et al.* Role of blue dye for sentinel lymph node detection in early endometrial cancer. *Gynecol Surg* 2017;14:23.
- 224 Sinno AK, Peijnenburg E, Fader AN, *et al.* Reducing overtreatment: a comparison of lymph node assessment strategies for endometrial cancer. *Gynecol Oncol* 2016;143:281–6.
- 225 Naoura I, Canlorbe G, Bendifallah S, *et al.* Relevance of sentinel lymph node procedure for patients with high-risk endometrial cancer. *Gynecol Oncol* 2015;136:60–4.
- 226 Papadia A, Gasparri ML, Radan AP, *et al.* Retrospective validation of the laparoscopic ICG SLN mapping in patients with grade 3 endometrial cancer. *J Cancer Res Clin Oncol* 2018;144:1385–93.
- 227 Papadia A, Gasparri ML, Siegenthaler F, *et al.* FIGO stage IIC endometrial cancer identification among patients with complex atypical hyperplasia, grade 1 and 2 endometrioid endometrial cancer: laparoscopic indocyanine green sentinel lymph node mapping versus frozen section of the uterus, why get around the problem? *J Cancer Res Clin Oncol* 2017;143:491–7.
- 228 Ghezzi F, Casarin J, Uccella S. Mini-laparoscopic sentinel node detection in endometrial cancer: further reducing invasiveness for patients with early-stage disease. *Ann Surg Oncol* 2015;22:S342.
- 229 Montero Macias R, Balaya V, Bonsang-Kitzis H, *et al.* Precaval positive sentinel lymph node with bilateral negative pelvic sentinel lymph node in low-risk endometrial cancer patient. *J Gynecol Obstet Hum Reprod* 2019;48.
- 230 Brugger S, Hamann M, Mosner M, *et al.* Endometrial cancer-how many patients could benefit from sentinel lymph node dissection? *World J Surg Oncol* 2018;16:95.
- 231 Kataoka F, Susumu N, Yamagami W, *et al.* The importance of para-aortic lymph nodes in sentinel lymph node mapping for endometrial cancer by using hysteroscopic radio-isotope tracer injection combined with subserosal dye injection: prospective study. *Gynecol Oncol* 2016;140:400–4.
- 232 Backes FJ, Cohen D, Salani R, *et al.* Prospective clinical trial of robotic sentinel lymph node assessment with isosulfane blue (ISB) and indocyanine green (ICG) in endometrial cancer and the impact of ultrastaging (NCT01818739). *Gynecol Oncol* 2019;153:496–9.
- 233 Togami S, Kawamura T, Fukuda M, *et al.* Prospective study of sentinel lymph node mapping for endometrial cancer. *Int J Gynecol Obstet* 2018;143:313–8.
- 234 Rajanbabu A, Agarwal R. A prospective evaluation of the sentinel node mapping algorithm in endometrial cancer and correlation of its performance against endometrial cancer risk subtypes. *Eur J Obstet Gynecol Reprod Biol* 2018;224:77–80.
- 235 Farzaneh F, Moridi A, Azizmohammadi Z, *et al.* Value of sentinel lymph node (SLN) mapping and biopsy using combined intracervical radiotracers and blue dye injections for endometrial cancer. *Asian Pac J Cancer Prev* 2017;18:431–5.
- 236 Holloway RW, Ahmad S, Kendrick JE, *et al.* A prospective cohort study comparing colorimetric and fluorescent imaging for sentinel lymph node mapping in endometrial cancer. *Ann Surg Oncol* 2017;24:1972–9.
- 237 Soliman PT, Westin SN, Dioun S, *et al.* A prospective validation study of sentinel lymph node mapping for high-risk endometrial cancer. *Gynecol Oncol* 2017;146:234–9.
- 238 Frati A, Ballester M, Dubernard G, *et al.* Contribution of lymphoscintigraphy for sentinel lymph node biopsy in women with early stage endometrial cancer: results of the SENTI-ENDO study. *Ann Surg Oncol* 2015;22:1980–6.
- 239 Hagen B, Valla M, Aune G, *et al.* Indocyanine green fluorescence imaging of lymph nodes during robotic-assisted laparoscopic operation for endometrial cancer. A prospective validation study using a sentinel lymph node surgical algorithm. *Gynecol Oncol* 2016;143:479–83.
- 240 Geppert B, Lönnerfors C, Bollino M, *et al.* Sentinel lymph node biopsy in endometrial cancer—feasibility, safety and lymphatic complications. *Gynecol Oncol* 2018;148:491–8.
- 241 Zuo J, Wu LY, Cheng M, *et al.* Comparison study of laparoscopic sentinel lymph node mapping in endometrial carcinoma using carbon nanoparticles and lymphatic pathway verification. *J Minim Invasive Gynecol* 2019;26:1125–32.
- 242 Accorsi GS, Paiva LL, Schmidt R, *et al.* Sentinel lymph node mapping vs systematic lymphadenectomy for endometrial cancer: surgical morbidity and lymphatic complications. *J Minim Invasive Gynecol* 2020;27:938–45.
- 243 Kim CH, Khoury-Collado F, Barber EL, *et al.* Sentinel lymph node mapping with pathologic ultrastaging: a valuable tool for assessing nodal metastasis in low-grade endometrial cancer with superficial myoinvasion. *Gynecol Oncol* 2013;131:714–9.
- 244 Cusimano MC, Vicus D, Pulman K, *et al.* Assessment of sentinel lymph node biopsy vs lymphadenectomy for intermediate- and high-grade endometrial cancer staging. *JAMA Surg* 2020. doi:10.1001/jamasurg.2020.5060. [Epub ahead of print: 11 Nov 2020].
- 245 Rozenholc A, Samouelian V, Warkus T, *et al.* Green versus blue: randomized controlled trial comparing indocyanine green with methylene blue for sentinel lymph node detection in endometrial cancer. *Gynecol Oncol* 2019;153:500–4.
- 246 Kang S, Yoo HJ, Hwang JH, *et al.* Sentinel lymph node biopsy in endometrial cancer: meta-analysis of 26 studies. *Gynecol Oncol* 2011;123:522–7.
- 247 Frumovitz M, Plante M, Lee PS, *et al.* Near-infrared fluorescence for detection of sentinel lymph nodes in women with cervical and uterine cancers (FILM): a randomised, phase 3, multicentre, non-inferiority trial. *Lancet Oncol* 2018;19:1394–403.
- 248 Ignatov A, Lebius C, Ignatov T, *et al.* Lymph node micrometastases and outcome of endometrial cancer. *Gynecol Oncol* 2019;154:475–9.
- 249 Kitchener H, Swart AMC, *et al.* ASTEC Study Group. Efficacy of systematic pelvic lymphadenectomy in endometrial cancer (MRC ASTEC trial): a randomised study. *Lancet* 2009;373:125–36.
- 250 Benedetti Panici P, Basile S, Maneschi F, *et al.* Systematic pelvic lymphadenectomy vs. no lymphadenectomy in early-stage endometrial carcinoma: randomized clinical trial. *J Natl Cancer Inst* 2008;100:1707–16.
- 251 Gu H, Li J, Gu Y, *et al.* Survival impact of ovarian preservation on women with early-stage endometrial cancer: a systematic review and meta-analysis. *Int J Gynecol Cancer* 2017;27:77–84.
- 252 Lyu T, Guo L, Chen X, *et al.* Ovarian preservation for premenopausal women with early-stage endometrial cancer: a Chinese retrospective study. *J Int Med Res* 2019;47:2492–8.
- 253 Lau H-Y, Chen M-Y, Ke Y-M, *et al.* Outcome of ovarian preservation during surgical treatment for endometrial cancer: a Taiwanese Gynecologic Oncology Group study. *Taiwan J Obstet Gynecol* 2015;54:532–6.
- 254 Kinyo Y, Kudaka W, Ooyama T, *et al.* Ovarian preservation in young women with endometrial cancer of endometrioid histology. *Acta Obstet Gynecol Scand* 2015;94:430–4.
- 255 Anggraeni TD, Al Fattah AN, Surya R. Prophylactic salpingectomy and ovarian cancer: an evidence-based analysis. *South Asian J Cancer* 2018;7:42–5.
- 256 Peccatori FA, Mangili G, Bergamini A, *et al.* Fertility preservation in women harboring deleterious BRCA mutations: ready for prime time? *Hum Reprod* 2018;33:181–7.
- 257 Liu T, Tu H, Li Y, *et al.* Impact of radical hysterectomy versus simple hysterectomy on survival of patients with stage 2 endometrial cancer: a meta-analysis. *Ann Surg Oncol* 2019;26:2933–42.
- 258 van der Steen-Banasik E, Christiaens M, Shash E, *et al.* Systemic review: radiation therapy alone in medical non-operable endometrial carcinoma. *Eur J Cancer* 2016;65:172–81.
- 259 Dutta SW, Trifiletti DM, Grover S, *et al.* Management of elderly patients with early-stage medically inoperable endometrial cancer: systematic review and National Cancer Database analysis. *Brachytherapy* 2017;16:526–33.
- 260 Acharya S, Perkins SM, DeWees T, *et al.* Brachytherapy is associated with improved survival in inoperable stage I endometrial adenocarcinoma: a population-based analysis. *Int J Radiat Oncol Biol Phys* 2015;93:649–57.
- 261 Schwarz JK, Beriwal S, Esthappan J, *et al.* Consensus statement for brachytherapy for the treatment of medically inoperable endometrial cancer. *Brachytherapy* 2015;14:587–99.
- 262 Gill BS, Kim H, Houser C, *et al.* Image-based three-dimensional conformal brachytherapy for medically inoperable endometrial carcinoma. *Brachytherapy* 2014;13:542–7.
- 263 Yang B, Xu Y, Zhu Q, *et al.* Treatment efficiency of comprehensive hysteroscopic evaluation and lesion resection combined with progestin therapy in young women with endometrial atypical hyperplasia and endometrial cancer. *Gynecol Oncol* 2019;153:55–62.
- 264 Chae SH, Shim S-H, Lee SJ, *et al.* Pregnancy and oncologic outcomes after fertility-sparing management for early stage endometrioid endometrial cancer. *Int J Gynecol Cancer* 2019;29:777–85.
- 265 Giampaolino P, Di Spiezio Sardo A, Mollo A, *et al.* Hysteroscopic endometrial focal resection followed by levonorgestrel intrauterine device insertion as a fertility-sparing treatment of atypical endometrial hyperplasia and early endometrial cancer: a retrospective study. *J Minim Invasive Gynecol* 2019;26:648–56.
- 266 Tamauchi S, Kajiyama H, Utsumi F, *et al.* Efficacy of medroxyprogesterone acetate treatment and retreatment for atypical endometrial hyperplasia and endometrial cancer. *J Obstet Gynaecol Res* 2018;44:151–6.

- 267 Kim SR, van der Zanden C, Ikiz H, *et al.* Fertility-sparing management using progestin for young women with endometrial cancer from a population-based study. *J Obstet Gynaecol Can* 2018;40:328–33.
- 268 Yamagami W, Susumu N, Makabe T, *et al.* Is repeated high-dose medroxyprogesterone acetate (MPA) therapy permissible for patients with early stage endometrial cancer or atypical endometrial hyperplasia who desire preserving fertility? *J Gynecol Oncol* 2018;29:e21.
- 269 Fan Z, Li H, Hu R, *et al.* Fertility-preserving treatment in young women with grade 1 presumed stage Ia endometrial adenocarcinoma: a meta-analysis. *Int J Gynecol Cancer* 2018;28:385–93.
- 270 Hwang JY, Kim DH, Bae HS, *et al.* Combined oral medroxyprogesterone/levonorgestrel-intrauterine system treatment for women with grade 2 stage Ia endometrial cancer. *Int J Gynecol Cancer* 2017;27:738–42.
- 271 Di Spiezio Sardo A, De Angelis MC, Della Corte L, *et al.* Should endometrial biopsy under direct hysteroscopic visualization using the GRASP technique become the new gold standard for the preoperative evaluation of the patient with endometrial cancer? *Gynecol Oncol* 2020;158:347–53.
- 272 Lago V, Martín B, Ballesteros E, *et al.* Tumor grade correlation between preoperative biopsy and final surgical specimen in endometrial cancer: the use of different diagnostic methods and analysis of associated factors. *Int J Gynecol Cancer* 2018;28:1258–63.
- 273 Larish A, Kumar A, Weaver A, *et al.* Impact of hysteroscopy on course of disease in high-risk endometrial carcinoma. *Int J Gynecol Cancer* 2020;30:1513–9.
- 274 Education and Practical Standards Committee, European Federation of Societies for Ultrasound in Medicine and Biology. Minimum training recommendations for the practice of medical ultrasound. *Ultraschall Med* 2006;27:79–105.
- 275 Kitson S, Ryan N, MacKintosh ML, *et al.* Interventions for weight reduction in obesity to improve survival in women with endometrial cancer. *Cochrane Database Syst Rev* 2018;2.
- 276 Raffone A, Travaglino A, Saccone G, *et al.* Diabetes mellitus and responsiveness of endometrial hyperplasia and early endometrial cancer to conservative treatment. *Gynecol Endocrinol* 2019;35:932–7.
- 277 Chu D, Wu J, Wang K, *et al.* Effect of metformin use on the risk and prognosis of endometrial cancer: a systematic review and meta-analysis. *BMC Cancer* 2018;18:438.
- 278 Greenwald ZR, Huang LN, Wissing MD, *et al.* Does hormonal therapy for fertility preservation affect the survival of young women with early-stage endometrial cancer? *Cancer* 2017;123:1545–54.
- 279 Wei J, Zhang W, Feng L, *et al.* Comparison of fertility-sparing treatments in patients with early endometrial cancer and atypical complex hyperplasia. *Medicine* 2017;96:e8034.
- 280 Zhang Q, Qi G, Kanis MJ, *et al.* Comparison among fertility-sparing therapies for well differentiated early-stage endometrial carcinoma and complex atypical hyperplasia. *Oncotarget* 2017;8:57642–53.
- 281 Zapardiel I, Cruz M, Diestro MD, *et al.* Assisted reproductive techniques after fertility-sparing treatments in gynaecological cancers. *Hum Reprod Update* 2016;22:281–305.
- 282 Marton I, Vranes HS, Sparac V, *et al.* Two cases of successful pregnancies after hysteroscopic removal of endometrioid adenocarcinoma grade I, stage Ia, in young women with Lynch syndrome. *J Turkish German Gynecol Assoc* 2014;15:63–6.
- 283 Casadio P, Guasina F, Talamo MR, *et al.* Conservative hysteroscopic treatment of stage I well differentiated endometrial cancer in patients with high surgical risk: a pilot study. *J Gynecol Oncol* 2019;30:e62.
- 284 Yang H-C, Liu J-C, Liu F-S. Fertility-preserving treatment of stage Ia, well-differentiated endometrial carcinoma in young women with hysteroscopic resection and high-dose progesterone therapy. *Taiwan J Obstet Gynecol* 2019;58:90–3.
- 285 Arendas K, Aldossary M, Cipolla A, *et al.* Hysteroscopic resection in the management of early-stage endometrial cancer: report of 2 cases and review of the literature. *J Minim Invasive Gynecol* 2015;22:34–9.
- 286 Casadio P, Guasina F, Paradisi R, *et al.* Fertility-sparing treatment of endometrial cancer with initial infiltration of myometrium by resectoscopic surgery: a pilot study. *Oncologist* 2018;23:478–80.
- 287 Leone Roberti Maggiore U, Martinelli F, Dondi G, *et al.* Efficacy and fertility outcomes of levonorgestrel-releasing intra-uterine system treatment for patients with atypical complex hyperplasia or endometrial cancer: a retrospective study. *J Gynecol Oncol* 2019;30:e57.
- 288 Pal N, Broaddus RR, Urbauer DL, *et al.* Treatment of low-risk endometrial cancer and complex atypical hyperplasia with the levonorgestrel-releasing intrauterine device. *Obstet Gynecol* 2018;131:109–16.
- 289 Sletten ET, Arnes M, Vereide AB, *et al.* Low-dose LNG-IUS as therapy for endometrial hyperplasia. A prospective cohort pilot study. *Anticancer Res* 2018;38:2883–9.
- 290 Ørbo A, Vereide AB, Arnes M, *et al.* Levonorgestrel-impregnated intrauterine device as treatment for endometrial hyperplasia: a national multicentre randomised trial. *BJOG: Int J Obstet Gynaecol* 2014;121:477–86.
- 291 Luo L, Luo B, Zheng Y, *et al.* Oral and intrauterine progestogens for atypical endometrial hyperplasia. *Cochrane Database Syst Rev* 2018;12.
- 292 Marnach ML, Butler KA, Henry MR, *et al.* Oral Progestogens Versus Levonorgestrel-Releasing Intrauterine System for Treatment of Endometrial Intraepithelial. *J Womens Health* 2017;26:368–73.
- 293 Kim MK, Seong SJ, Kang S-B, *et al.* Six months response rate of combined oral medroxyprogesterone/levonorgestrel-intrauterine system for early-stage endometrial cancer in young women: a Korean Gynecologic-Oncology Group study. *J Gynecol Oncol* 2019;30:e47.
- 294 Tock S, Jadoul P, Squifflet J-L, *et al.* Fertility sparing treatment in patients with early stage endometrial cancer, using a combination of surgery and GnRH agonist: a monocentric retrospective study and review of the literature. *Front Med* 2018;5.
- 295 Jadoul P, Donnez J. Conservative treatment may be beneficial for young women with atypical endometrial hyperplasia or endometrial adenocarcinoma. *Fertil Steril* 2003;80:1315–24.
- 296 Stewart CJR, Crum CP, McCluggage WG, *et al.* Guidelines to aid in the distinction of endometrial and endocervical carcinomas, and the distinction of independent primary carcinomas of the endometrium and adnexa from metastatic spread between these and other sites. *Int J Gynecol Pathol* 2019;38 Suppl 1:S75–92.
- 297 Connell PP, Rotmensch J, Waggoner S, *et al.* The significance of adnexal involvement in endometrial carcinoma. *Gynecol Oncol* 1999;74:74–9.
- 298 Soliman PT, Slomovitz BM, Broaddus RR, *et al.* Synchronous primary cancers of the endometrium and ovary: a single institution review of 84 cases. *Gynecol Oncol* 2004;94:456–62.
- 299 Schultheis AM, Ng CKY, De Filippo MR, *et al.* Massively parallel sequencing-based clonality analysis of synchronous endometrioid endometrial and ovarian carcinomas. *J Natl Cancer Inst* 2016;108:djv427.
- 300 Anglesio MS, Wang YK, Maassen M, *et al.* Synchronous endometrial and ovarian carcinomas: evidence of clonality. *J Natl Cancer Inst* 2016;108:djv428.
- 301 Turashvili G, Gómez-Hidalgo NR, Flynn J, *et al.* Risk-based stratification of carcinomas concurrently involving the endometrium and ovary. *Gynecol Oncol* 2019;152:38–45.
- 302 Keys HM, Roberts JA, Brunetto VL, *et al.* A phase III trial of surgery with or without adjunctive external pelvic radiation therapy in intermediate risk endometrial adenocarcinoma: a Gynecologic Oncology Group study. *Gynecol Oncol* 2004;92:744–51.
- 303 Creutzberg CL, van Putten WLJ, Koper PCM, *et al.* Surgery and postoperative radiotherapy versus surgery alone for patients with stage-1 endometrial carcinoma: multicentre randomised trial. *The Lancet* 2000;355:1404–11.
- 304 Aalders J, Abeler V, Kolstad P, *et al.* Postoperative external irradiation and prognostic parameters in stage I endometrial carcinoma: clinical and histopathologic study of 540 patients. *Obstet Gynecol* 1980;56:419–27.
- 305 Blake P, Swart AM, *et al.* ASTEC/EN.5 Study Group. Adjuvant external beam radiotherapy in the treatment of endometrial cancer (MRC ASTEC and NCIC CTG EN.5 randomised trials): pooled trial results, systematic review, and meta-analysis. *Lancet* 2009;373:137–46.
- 306 Barney BM, Petersen IA, Mariani A, *et al.* The role of vaginal brachytherapy in the treatment of surgical stage I papillary serous or clear cell endometrial cancer. *Int J Radiat Oncol Biol Phys* 2013;85:109–15.
- 307 Wortman BG, Creutzberg CL, Putter H, *et al.* Ten-year results of the PORTEC-2 trial for high-intermediate risk endometrial carcinoma: improving patient selection for adjuvant therapy. *Br J Cancer* 2018;119:1067–74.
- 308 Nout RA, Smit V, Putter H, *et al.* Vaginal brachytherapy versus pelvic external beam radiotherapy for patients with endometrial cancer of high-intermediate risk (PORTEC-2): an open-label, non-inferiority, randomised trial. *The Lancet* 2010;375:816–23.
- 309 Sunil RA, Bhavsar D, Shruthi MN, *et al.* Combined external beam radiotherapy and vaginal brachytherapy versus vaginal

- brachytherapy in stage I, intermediate- and high-risk cases of endometrium carcinoma. *J Contemp Brachytherapy* 2018;10:105–14.
- 310 Cham S, Huang Y, Tergas AI, et al. Utility of radiation therapy for early-stage uterine papillary serous carcinoma. *Gynecol Oncol* 2017;145:269–76.
- 311 Shinde A, Li R, Amini A, et al. Improved survival with adjuvant brachytherapy in stage Ia endometrial cancer of unfavorable histology. *Gynecol Oncol* 2018;151:82–90.
- 312 Qu XM, Velker VM, Leung E, et al. The role of adjuvant therapy in stage Ia serous and clear cell uterine cancer: a multi-institutional pooled analysis. *Gynecol Oncol* 2018;149:283–90.
- 313 Donovan E, Reade CJ, Eiriksson LR, et al. Outcomes of adjuvant therapy for stage Ia serous endometrial cancer. *Cureus* 2018;10:e3387.
- 314 Sorbe B, Horvath G, Andersson H, et al. External pelvic and vaginal irradiation versus vaginal irradiation alone as postoperative therapy in medium-risk endometrial carcinoma—a prospective randomized study. *Int J Radiat Oncol Biol Phys* 2012;82:1249–55.
- 315 Ørtoft G, Hansen ES, Bertelsen K. Omitting adjuvant radiotherapy in endometrial cancer increases the rate of locoregional recurrences but has no effect on long-term survival: the Danish endometrial cancer study. *Int J Gynecol Cancer* 2013;23:1429–37.
- 316 Randall ME, Filiaci V, McMeekin DS, et al. Phase III trial: adjuvant pelvic radiation therapy versus vaginal brachytherapy plus paclitaxel/carboplatin in high-intermediate and high-risk early-stage endometrial cancer. *JCO* 2019;37:1810–8.
- 317 Maggi R, Lissoni A, Spina F, et al. Adjuvant chemotherapy vs radiotherapy in high-risk endometrial carcinoma: results of a randomised trial. *Br J Cancer* 2006;95:266–71.
- 318 Susumu N, Sagae S, Udagawa Y, et al. Randomized phase III trial of pelvic radiotherapy versus cisplatin-based combined chemotherapy in patients with intermediate- and high-risk endometrial cancer: a Japanese Gynecologic Oncology Group study. *Gynecol Oncol* 2008;108:226–33.
- 319 Hogberg T, Signorelli M, de Oliveira CF, et al. Sequential adjuvant chemotherapy and radiotherapy in endometrial cancer—Results from two randomised studies. *Eur J Cancer* 2010;46:2422–31.
- 320 de Boer SM, Powell ME, Mileskin L, et al. Adjuvant chemoradiotherapy versus radiotherapy alone for women with high-risk endometrial cancer (PORTEC-3): final results of an international, open-label, multicentre, randomised, phase 3 trial. *Lancet Oncol* 2018;19:295–309.
- 321 León-Castillo A, de Boer SM, Powell ME, et al. Molecular classification of the PORTEC-3 trial for high-risk endometrial cancer: impact on prognosis and benefit from adjuvant therapy. *JCO* 2020;38:3388–97.
- 322 Randall M, Filiaci V, McMeekin D, et al. A phase 3 trial of pelvic radiation therapy versus vaginal cuff brachytherapy followed by paclitaxel/carboplatin chemotherapy in patients with high-risk, early-stage endometrial cancer: a Gynecology Oncology Group study. *Int J Radiat Oncol Biol Phys* 2017;99:1313.
- 323 de Boer SM, Powell ME, Mileskin L, et al. Adjuvant chemoradiotherapy versus radiotherapy alone in women with high-risk endometrial cancer (PORTEC-3): patterns of recurrence and post-hoc survival analysis of a randomised phase 3 trial. *Lancet Oncol* 2019;20:1273–85.
- 324 Matei D, Filiaci V, Randall ME, et al. Adjuvant chemotherapy plus radiation for locally advanced endometrial cancer. *N Engl J Med Overseas Ed* 2019;380:2317–26.
- 325 Randall ME, Filiaci V, McMeekin DS, et al. Phase III trial: adjuvant pelvic radiation therapy versus vaginal brachytherapy plus paclitaxel/carboplatin in high-intermediate and high-risk early stage endometrial cancer. *J Clin Oncol* 2019;37:1810–8.
- 326 Albeesh R, Turgeon G-A, Alfieri J, et al. Adjuvant therapy in stage III endometrial cancer confined to the pelvis. *Gynecol Oncol* 2019;152:26–30.
- 327 Onal C, Yildirim BA, Sari SY, et al. Treatment outcomes of endometrial cancer patients with paraaortic lymph node metastasis: a multi-institutional analysis. *Int J Gynecol Cancer* 2019;29:94–101.
- 328 Scharl S, Papatthemelis T, Kronberger K, et al. Does post-operative radiochemotherapy improve survival in high-grade endometrial cancer patients? Results of a population-based cohort analysis of a cancer registry. *Arch Gynecol Obstet* 2018;297:1245–53.
- 329 Bonadio RR da CC, Azevedo R, Harada G. Adjuvant carboplatin and paclitaxel chemotherapy followed by radiotherapy in high-risk endometrial cancer: a retrospective analysis. *J Glob Oncol* 2018;4:1–8.
- 330 Chapman BV, Swanick CW, Ning MS, et al. Adjuvant combined-modality therapy for stage IIIC endometrioid and non-endometrioid endometrial cancer. *Gynecol Oncol* 2019;154:22–8.
- 331 Binder PS, Kuroki LM, Zhao P, et al. Benefit of combination chemotherapy and radiation stratified by grade of stage IIIC endometrial cancer. *Gynecol Oncol* 2017;147:309–14.
- 332 Lee JK, Mahan M, Hanna RK, et al. Survival outcomes and patterns of failure in women with stage IIIC2 endometrial carcinoma. *Eur J Obstet Gynecol Reprod Biol* 2017;216:192–7.
- 333 Signorelli M, Lissoni AA, De Ponti E, et al. Adjuvant sequential chemo and radiotherapy improves the oncological outcome in high risk endometrial cancer. *J Gynecol Oncol* 2015;26:284–92.
- 334 Bogani G, Cromi A, Serati M, et al. Chemotherapy reduces para-aortic node recurrences in endometrial cancer with positive pelvic and unknown para-aortic nodes. *Int J Gynecol Cancer* 2015;25:263–8.
- 335 Lee LJ, Bu P, Feltmate C, et al. Adjuvant chemotherapy with external beam radiation therapy for high-grade, node-positive endometrial cancer. *Int J Gynecol Cancer* 2014;24:1441–8.
- 336 Bakkum-Gamez JN, Mariani A, Dowdy SC, et al. Efficacy of contemporary chemotherapy in stage IIIC endometrial cancer: a histologic dichotomy. *Gynecol Oncol* 2014;132:578–84.
- 337 Xiang M, English DP, Kidd EA. National patterns of care and cancer-specific outcomes of adjuvant treatment in patients with serous and clear cell endometrial carcinoma. *Gynecol Oncol* 2019;152:599–604.
- 338 Holloway CL, Alexander C, Walter C, et al. Stage IIIC endometrial cancer: relapse and survival outcomes in women treated with pelvic or extended field para-aortic nodal radiation therapy. *Am J Clin Oncol* 2017;40:458–63.
- 339 Chen J-R, Chang T-C, Fu H-C, et al. Outcomes of patients with surgically and pathologically staged IIIA-IVB pure endometrioid-type endometrial cancer: a Taiwanese Gynecology Oncology Group (TGOG-2005) retrospective cohort study (a STROBE-compliant article). *Medicine* 2016;95:e3330.
- 340 Fleming ND, Soliman PT, Westin SN, et al. Impact of lymph node ratio and adjuvant therapy in node-positive endometrioid endometrial cancer. *Int J Gynecol Cancer* 2015;25:1437–44.
- 341 Boothe D, Orton A, Odei B, et al. Chemoradiation versus chemotherapy or radiation alone in stage III endometrial cancer: patterns of care and impact on overall survival. *Gynecol Oncol* 2016;141:421–7.
- 342 Boothe D, Orton A, Odei B, et al. Corrigendum to “Chemoradiation versus chemotherapy or radiation alone in stage III endometrial cancer: Patterns of care and impact on overall survival” [Gynecol. Oncol. 141 (2016) 421–427]. *Gynecol Oncol* 2016;143:690–1.
- 343 Wong AT, Rineer J, Lee Y-C, et al. Utilization of adjuvant therapies and their impact on survival for women with stage IIIC endometrial adenocarcinoma. *Gynecol Oncol* 2016;142:514–9.
- 344 Lin JF, Muñoz K, Sukumvanich P, et al. Survival advantage associated with multimodal therapy in women with node-positive (stage-IIIC) uterine papillary serous carcinoma: a National Cancer Database study. *Int J Obstet Gynaecol* 2016;123:1846–52.
- 345 Barlin JN, Puri I, Bristow RE. Cytoreductive surgery for advanced or recurrent endometrial cancer: a meta-analysis. *Gynecol Oncol* 2010;118:14–18.
- 346 Rajkumar S, Nath R, Lane G, et al. Advanced stage (IIIC/IV) endometrial cancer: role of cytoreduction and determinants of survival. *Eur J Obstet Gynecol Reprod Biol* 2019;234:26–31.
- 347 Solmaz U, Mat E, Dereli ML, et al. Stage-III and -IV endometrial cancer: a single oncology centre review of 104 cases. *J Obstet Gynaecol* 2016;36:81–6.
- 348 Cirik DA, Karalok A, Ureyen I, et al. Stage IVb endometrial cancer confined to the abdomen: is chemotherapy superior to radiotherapy? *Eur J Gynaecol Oncol* 2016;37:226–31.
- 349 Schmidt A-M, Imesch P, Fink D, et al. Pelvic exenterations for advanced and recurrent endometrial cancer: clinical outcomes of 40 patients. *Int J Gynecol Cancer* 2016;26:716–21.
- 350 Vitale SG, Valenti G, Gulino FA, et al. Surgical treatment of high stage endometrial cancer: current perspectives. *Updates Surg* 2016;68:149–54.
- 351 Tangjitgamol S, Kittisiam T, Sriraumpuch J. Impact of metastatic lymph node to total lymph node ratio on survival of endometrial cancer patients. *Gynecol Obstet Invest* 2019;84:463–71.
- 352 Yoon MS, Park W, Huh SJ, et al. Impact of paraaortic lymphadenectomy for endometrial cancer with positive pelvic lymph nodes: a Korean Radiation Oncology Group study (KROG 13-17). *Eur J Surg Oncol* 2016;42:1497–505.
- 353 Bogani G, Ditto A, Maggiore ULR, et al. Neoadjuvant chemotherapy followed by interval debulking surgery for unresectable stage IVb serous endometrial cancer. *Tumori* 2019;105:92–7.

- 354 Boisen MM, Vargo JA, Beriwal S, *et al.* Surgical outcomes of patients undergoing extrafascial hysterectomy after neoadjuvant radiotherapy with or without chemotherapy for locally advanced endometrial cancer clinically extending to the cervix or parametria. *Int J Gynecol Cancer* 2017;27:1149–54.
- 355 De Lange NM, Ezendam NPM, Kwon JS, *et al.* Neoadjuvant chemotherapy followed by surgery for advanced-stage endometrial cancer. *Curr Oncol* 2019;26:e226–32.
- 356 Iheagwara UK, Vargo JA, Chen KS, *et al.* Neoadjuvant chemoradiation therapy followed by extrafascial hysterectomy in locally advanced type II endometrial cancer clinically extending to cervix. *Pract Radiat Oncol* 2019;9:248–56.
- 357 Khouri OR, Frey MK, Musa F, *et al.* Neoadjuvant chemotherapy in patients with advanced endometrial cancer. *Cancer Chemother Pharmacol* 2019;84:281–5.
- 358 Palisoul M, Mutch DG. The clinical management of inoperable endometrial carcinoma. *Expert Rev Anticancer Ther* 2016;16:515–21.
- 359 Rabinovich A. Neo-adjuvant chemotherapy for advanced stage endometrial carcinoma: a glimmer of hope in select patients. *Arch Gynecol Obstet* 2016;293:47–53.
- 360 Vandenput I, Van Calster B, Capoen A, *et al.* Neoadjuvant chemotherapy followed by interval debulking surgery in patients with serous endometrial cancer with transperitoneal spread (stage IV): a new preferred treatment? *Br J Cancer* 2009;101:244–9.
- 361 Conway JL, Lukovic J, Laframboise S, *et al.* Brachy-ing unresectable endometrial cancers with magnetic resonance guidance. *Cureus* 2018;10:e2274.
- 362 Townamchai K, Poorvu PD, Damato AL, *et al.* Radiation dose escalation using intensity modulated radiation therapy for gross unresected node-positive endometrial cancer. *Pract Radiat Oncol* 2014;4:90–8.
- 363 Francis SR, Ager BJ, Do OA, *et al.* Recurrent early stage endometrial cancer: patterns of recurrence and results of salvage therapy. *Gynecol Oncol* 2019;154:38–44.
- 364 Hardarson HA, Heidemann LN, dePont Christensen R, *et al.* Vaginal vault recurrences of endometrial cancer in non-irradiated patients – radiotherapy or surgery. *Gynecol Oncol Rep* 2015;11:26–30.
- 365 Shikama A, Minaguchi T, Takao W, *et al.* Predictors of favorable survival after secondary cytoreductive surgery for recurrent endometrial cancer. *Int J Clin Oncol* 2019;24:1256–63.
- 366 Turan T, Tasci T, Karalok A, *et al.* Salvage cytoreductive surgery for recurrent endometrial cancer. *Int J Gynecol Cancer* 2015;25:1623–32.
- 367 Ren Y, Shan B, Shi D, *et al.* Salvage cytoreductive surgery for patients with recurrent endometrial cancer: a retrospective study. *BMC Cancer* 2014;14:135.
- 368 Papadia A, Bellati F, Ditto A, *et al.* Surgical treatment of recurrent endometrial cancer: time for a paradigm shift. *Ann Surg Oncol* 2015;22:4204–10.
- 369 Domenici L, Nixon K, Sorbi F, *et al.* Surgery for recurrent uterine cancer: surgical outcomes and implications for survival—a case series. *Int J Gynecol Cancer* 2017;27:759–67.
- 370 Baek S, Isohashi F, Yamaguchi H, *et al.* Salvage high-dose-rate brachytherapy for isolated vaginal recurrence of endometrial cancer. *Brachytherapy* 2016;15:812–6.
- 371 Chapman CH, Maghsoudi K, Littell RD, *et al.* Salvage high-dose-rate brachytherapy and external beam radiotherapy for isolated vaginal recurrences of endometrial cancer with no prior adjuvant therapy. *Brachytherapy* 2017;16:1152–8.
- 372 Fokdal L, Ørtoft G, Hansen ES, *et al.* Toward four-dimensional image-guided adaptive brachytherapy in locally recurrent endometrial cancer. *Brachytherapy* 2014;13:554–61.
- 373 Ho JC, Allen PK, Jhingran A, *et al.* Management of nodal recurrences of endometrial cancer with IMRT. *Gynecol Oncol* 2015;139:40–6.
- 374 Huang K, D'Souza D, Patil N, *et al.* High-dose-rate interstitial brachytherapy for the treatment of high-volume locally recurrent endometrial carcinoma. *Brachytherapy* 2016;15:543–8.
- 375 Kamran SC, Manuel MM, Catalano P, *et al.* MR- versus CT-based high-dose-rate interstitial brachytherapy for vaginal recurrence of endometrial cancer. *Brachytherapy* 2017;16:1159–68.
- 376 Sekii S, Murakami N, Kato T, *et al.* Outcomes of salvage high-dose-rate brachytherapy with or without external beam radiotherapy for isolated vaginal recurrence of endometrial cancer. *J Contemp Brachytherapy* 2017;3:209–15.
- 377 Vargo JA, Kim H, Houser CJ, *et al.* Definitive salvage for vaginal recurrence of endometrial cancer: the impact of modern intensity-modulated-radiotherapy with image-based HDR brachytherapy and the interplay of the PORTEC 1 risk stratification. *Radiother Oncol* 2014;113:126–31.
- 378 Viswanathan AN, Lee H, Berkowitz R, *et al.* A prospective feasibility study of radiation and concurrent bevacizumab for recurrent endometrial cancer. *Gynecol Oncol* 2014;132:55–60.
- 379 Yanazume S, Arimura T, Kobayashi H, *et al.* Potential proton beam therapy for recurrent endometrial cancer in the vagina. *J Obstet Gynaecol Res* 2015;41:813–6.
- 380 Chiantera V, Rossi M, De Iaco P, *et al.* Pelvic exenteration for recurrent endometrial adenocarcinoma: a retrospective multi-institutional study about 21 patients. *Int J Gynecol Cancer* 2014;24:880–4.
- 381 Margolis B, Kim SW, Chi DS. Long-term survival after anterior pelvic exenteration and total vaginectomy for recurrent endometrial carcinoma with metastatic inguinal nodes at the time of surgery. *Gynecol Oncol Rep* 2017;19:39–41.
- 382 Ling DC, Vargo JA, Glaser SM, *et al.* Outcomes after definitive re-irradiation with 3D brachytherapy with or without external beam radiation therapy for vaginal recurrence of endometrial cancer. *Gynecol Oncol* 2019;152:581–6.
- 383 Mabuchi S, Takahashi R, Isohashi F, *et al.* Reirradiation using high-dose-rate interstitial brachytherapy for locally recurrent cervical cancer: a single institutional experience. *Int J Gynecol Cancer* 2014;24:141–8.
- 384 Arians N, Foerster R, Rom J, *et al.* Outcome of patients with local recurrent gynecologic malignancies after resection combined with intraoperative electron radiation therapy (IOERT). *Radiat Oncol* 2016;11.
- 385 Feddock J, Cheek D, Steber C, *et al.* Reirradiation using permanent interstitial brachytherapy: a potentially durable technique for salvage recurrent pelvic malignancies. *Int J Radiat Oncol Biol Phys* 2017;99:1225–33.
- 386 Wooten CE, Randall M, Edwards J, *et al.* Implementation and early clinical results utilizing Cs-131 permanent interstitial implants for gynecologic malignancies. *Gynecol Oncol* 2014;133:268–73.
- 387 Widder J, Lodeweges J. Synchronous or metachronous oligometastases. *J Thorac Oncol* 2017;12:e191–2.
- 388 Xu L, Burke AP. Pulmonary oligometastases: histological features and difficulties in determining site of origin. *Int J Surg Pathol* 2012;20:577–88.
- 389 Kaneda H, Saito Y. Oligometastases: defined by prognosis and evaluated by cure. *Cancer Treat Commun* 2015;3:1–6.
- 390 Kunos CA, Brindle J, Waggoner S, *et al.* Phase II clinical trial of robotic stereotactic body radiosurgery for metastatic gynecologic malignancies. *Front Oncol* 2012;2:181.
- 391 Lodeweges JE, Klinkenberg TJ, Ubbels JF, *et al.* Long-term outcome of surgery or stereotactic radiotherapy for lung oligometastases. *J Thorac Oncol* 2017;12:1442–5.
- 392 Palma DA, Olson R, Harrow S, *et al.* Stereotactic ablative radiotherapy versus standard of care palliative treatment in patients with oligometastatic cancers (SABR-COMET): a randomised, phase 2, open-label trial. *Lancet* 2019;393:2051–8.
- 393 Loveman E, Jones J, Clegg AJ, *et al.* The clinical effectiveness and cost-effectiveness of ablative therapies in the management of liver metastases: systematic review and economic evaluation. *Health Technol Assess* 2014;18:1–283.
- 394 van Weelden WJ, Massuger LFAG, *et al.* ENITEC. Anti-estrogen treatment in endometrial cancer: a systematic review. *Front Oncol* 2019;9:359.
- 395 Ethier J-L, Desautels DN, Amir E, *et al.* Is hormonal therapy effective in advanced endometrial cancer? A systematic review and meta-analysis. *Gynecol Oncol* 2017;147:158–66.
- 396 Mileskin L, Edmondson R, O'Connell RL, *et al.* Phase 2 study of anastrozole in recurrent estrogen (ER)/progesterone (PR) positive endometrial cancer: The PARAGON trial – ANZGOG 0903. *Gynecol Oncol* 2019;154:29–37.
- 397 Slomovitz BM, Jiang Y, Yates MS, *et al.* Phase II study of everolimus and letrozole in patients with recurrent endometrial carcinoma. *JCO* 2015;33:930–6.
- 398 Miller DFV, Filiaci V, Fleming G, *et al.* Randomized phase III non inferiority trial of first line chemotherapy for metastatic or recurrent endometrial carcinoma: a gynecologic oncology group study. [SGO abstract Late-Breaking Abstract 1]. *Gynecol Oncol* 2012;125S:771–3.
- 399 Rubinstein M, Halpenny D, Makker V, *et al.* Retreatment with carboplatin and paclitaxel for recurrent endometrial cancer: a retrospective study of the Memorial Sloan Kettering Cancer Center experience. *Gynecol Oncol Rep* 2019;28:120–3.
- 400 Marabelle A, Le DT, Ascierio PA, *et al.* Efficacy of pembrolizumab in patients with noncolorectal high microsatellite instability/mismatch repair-deficient cancer: results from the phase II KEYNOTE-158 study. *J Clin Oncol* 2020;38:1–10.

- 401 Mittica G, Ghisoni E, Giannone G, *et al.* Checkpoint inhibitors in endometrial cancer: preclinical rationale and clinical activity. *Oncotarget* 2017;8:90532–44.
- 402 Makker V, Taylor MH, Aghajanian C, *et al.* Lenvatinib plus pembrolizumab in patients with advanced endometrial cancer. *J Clin Oncol* 2020;38:2981–92.
- 403 Makker V, Rasco D, Vogelzang NJ, *et al.* Lenvatinib plus pembrolizumab in patients with advanced endometrial cancer: an interim analysis of a multicentre, open-label, single-arm, phase 2 trial. *Lancet Oncol* 2019;20:711–8.
- 404 Fader AN, Roque DM, Siegel E, *et al.* Randomized phase II trial of carboplatin-paclitaxel versus carboplatin-paclitaxel-trastuzumab in uterine serous carcinomas that overexpress human epidermal growth factor receptor 2/neu. *J Clin Oncol* 2018;36:2044–51.
- 405 Roncolato F, Lindemann K, Willson ML, *et al.* PI3K/Akt/mTOR inhibitors for advanced or recurrent endometrial cancer. *Cochrane Database Syst Rev* 2019;10.
- 406 Coleman RL, Sill MW, Thaker PH, *et al.* A phase II evaluation of selumetinib (AZD6244, ARRY-142886), a selective MEK-1/2 inhibitor in the treatment of recurrent or persistent endometrial cancer: an NRG Oncology/Gynecologic Oncology Group study. *Gynecol Oncol* 2015;138:30–5.
- 407 Bender D, Sill MW, Lankes HA, *et al.* A phase II evaluation of cediranib in the treatment of recurrent or persistent endometrial cancer: an NRG Oncology/Gynecologic Oncology Group study. *Gynecol Oncol* 2015;138:507–12.
- 408 Dizon DS, Sill MW, Schilder JM, *et al.* A phase II evaluation of nintedanib (BIBF-1120) in the treatment of recurrent or persistent endometrial cancer: an NRG Oncology/Gynecologic Oncology Group study. *Gynecol Oncol* 2014;135:441–5.
- 409 Castonguay V, Lheureux S, Welch S, *et al.* A phase II trial of sunitinib in women with metastatic or recurrent endometrial carcinoma: a study of the Princess Margaret, Chicago and California consortia. *Gynecol Oncol* 2014;134:274–80.
- 410 Powell MA, Sill MW, Goodfellow PJ, *et al.* A phase II trial of brivanib in recurrent or persistent endometrial cancer: an NRG Oncology/Gynecologic Oncology Group study. *Gynecol Oncol* 2014;135:38–43.
- 411 Oza AM, Elit L, Tsao M-S, *et al.* Phase II study of temsirolimus in women with recurrent or metastatic endometrial cancer: a trial of the NCIC Clinical Trials Group. *J Clin Oncol* 2011;29:3278–85.
- 412 Slomovitz BM, Lu KH, Johnston T, *et al.* A phase 2 study of the oral mammalian target of rapamycin inhibitor, everolimus, in patients with recurrent endometrial carcinoma. *Cancer* 2010;116:5415–9.
- 413 Emons G, Kurzeder C, Schmalfeldt B, *et al.* Temsirolimus in women with platinum-refractory/resistant ovarian cancer or advanced/recurrent endometrial carcinoma. A phase II study of the AGO-study group (AGO-GYN8). *Gynecol Oncol* 2016;140:450–6.
- 414 Tsoref D, Welch S, Lau S, *et al.* Phase II study of oral ridaforolimus in women with recurrent or metastatic endometrial cancer. *Gynecol Oncol* 2014;135:184–9.
- 415 Matulonis U, Vergote I, Backes F, *et al.* Phase II study of the PI3K inhibitor pilaralisib (SAR245408; XL147) in patients with advanced or recurrent endometrial carcinoma. *Gynecol Oncol* 2015;136:246–53.
- 416 Aghajanian C, Filiaci V, Dizon DS, *et al.* A phase II study of frontline paclitaxel/carboplatin/bevacizumab, paclitaxel/carboplatin/temsirolimus, or ixabepilone/carboplatin/bevacizumab in advanced/recurrent endometrial cancer. *Gynecol Oncol* 2018;150:274–81.
- 417 Sapienza LG, Ning MS, Jhingran A, *et al.* Short-course palliative radiation therapy leads to excellent bleeding control: a single centre retrospective study. *Clin Transl Radiat Oncol* 2019;14:40–6.
- 418 Klopp AH, Yeung AR, Deshmukh S, *et al.* Patient-reported toxicity during pelvic intensity-modulated radiation therapy: NRG Oncology-RTOG 1203. *J Clin Oncol* 2018;36:2538–44.
- 419 Klopp A, Smith BD, Alektiar K, *et al.* The role of postoperative radiation therapy for endometrial cancer: Executive summary of an American Society for Radiation Oncology evidence-based guideline. *Pract Radiat Oncol* 2014;4:137–44.
- 420 Harkenrider MM, Block AM, Alektiar KM, *et al.* American Brachytherapy Task Group report: adjuvant vaginal brachytherapy for early-stage endometrial cancer: a comprehensive review. *Brachytherapy* 2017;16:95–108.
- 421 Sturdza A, Viswanathan AN, Erickson B, *et al.* American Brachytherapy Society Working Group report on the patterns of care and a literature review of reirradiation for gynecologic cancers. *Brachytherapy* 2020;19:127–38.
- 422 Schmid MP, Fokdal L, Westerveld H, *et al.* Recommendations from gynaecological (GYN) GEC-ESTRO working group - ACROP: target concept for image guided adaptive brachytherapy in primary vaginal cancer. *Radiother Oncol* 2020;145:36–44.
- 423 Mendez LC, Leung E, Cheung P, *et al.* The role of stereotactic ablative body radiotherapy in gynaecological cancers: a systematic review. *Clin Oncol* 2017;29:378–84.
- 424 Hymel R, Jones GC, Simone CB. Whole pelvic intensity-modulated radiotherapy for gynecological malignancies: a review of the literature. *Crit Rev Oncol Hematol* 2015;94:371–9.
- 425 Köbel M, Ronnett BM, Singh N, *et al.* Interpretation of p53 immunohistochemistry in endometrial carcinomas: toward increased reproducibility. *Int J Gynecol Pathol* 2019;38 Suppl 1:S123–31.
- 426 Singh N, Hirschowitz L, Zaino R, *et al.* Pathologic prognostic factors in endometrial carcinoma (other than tumor type and grade). *Int J Gynecol Pathol* 2019;38 Suppl 1:S93–113.
- 427 Malpica A, Euscher ED, Hecht JL, *et al.* Endometrial carcinoma, grossing and processing issues: recommendations of the International Society of Gynecologic Pathologists. *Int J Gynecol Pathol* 2019;38 Suppl 1:S9–24.
- 428 McCluggage WG, Colgan T, Duggan M, *et al.* Data set for reporting of endometrial carcinomas: recommendations from the International Collaboration on Cancer Reporting (ICCR) between United Kingdom, United States, Canada, and Australasia. *Int J Gynecol Pathol* 2013;32:45–65.
- 429 Soslow RA, Tornos C, Park KJ, *et al.* Endometrial carcinoma diagnosis: use of FIGO grading and genomic subcategories in clinical practice: recommendations of the International Society of Gynecological Pathologists. *Int J Gynecol Pathol* 2019;38 Suppl 1:S64–74.
- 430 Weis J, Hasenburg A. Psychological support. In: Ayhan AR, Gultekin N, Dursun P, eds. *Textbook of gynaecological oncology*. Copenhagen: Gunes Publishing, 2016: 1495–9.
- 431 Andersen BL, DeRubeis RJ, Berman BS, *et al.* Screening, assessment, and care of anxiety and depressive symptoms in adults with cancer: an American Society of Clinical Oncology guideline adaptation. *J Clin Oncol* 2014;32:1605–19.
- 432 Donovan KA, Grassi L, McGinty HL, *et al.* Validation of the distress thermometer worldwide: state of the science. *Psychooncology* 2014;23:241–50.